

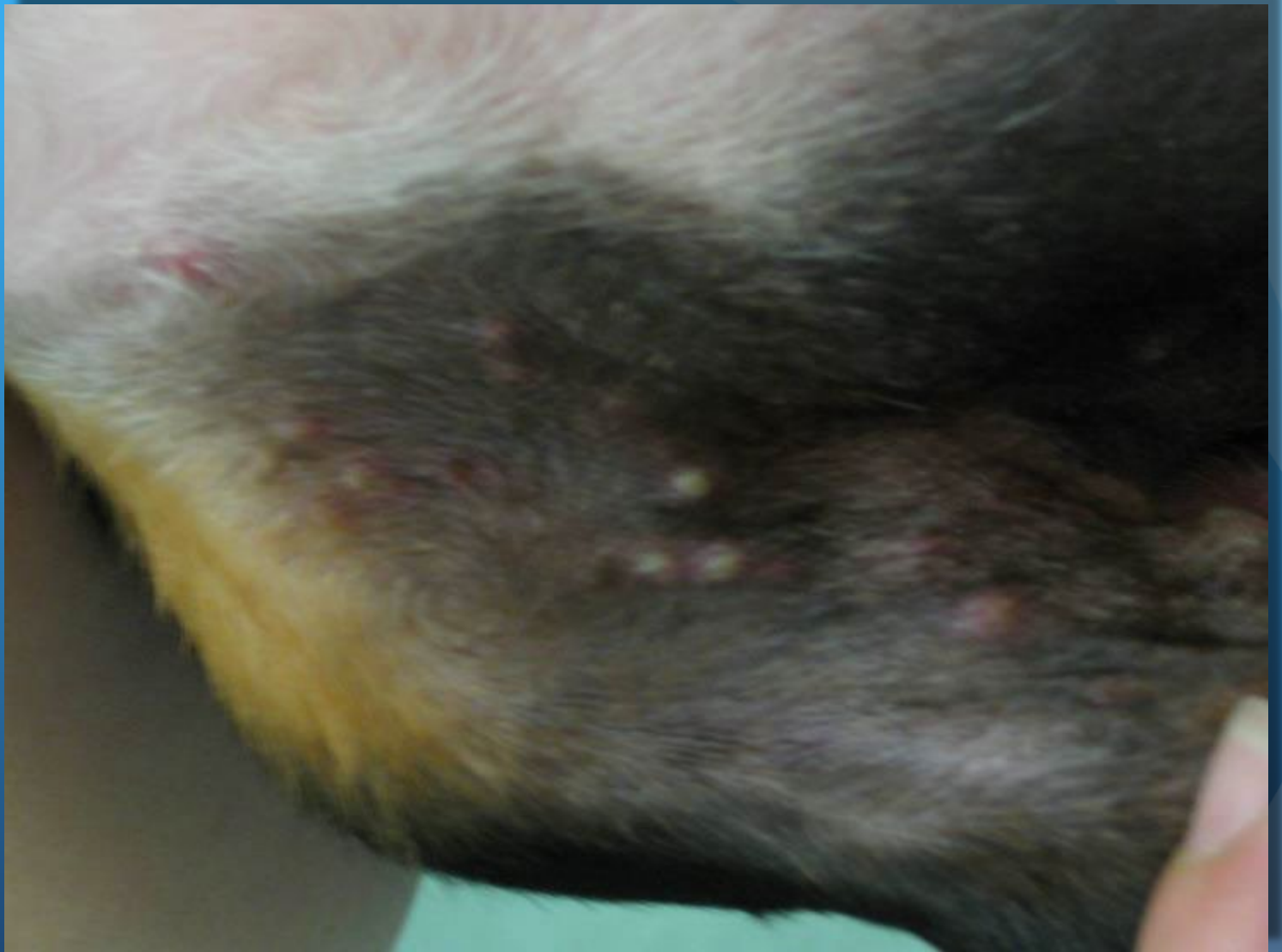# All that itches.... May not be allergic.

Chris Reeder, DVM  
Diplomate ACVD

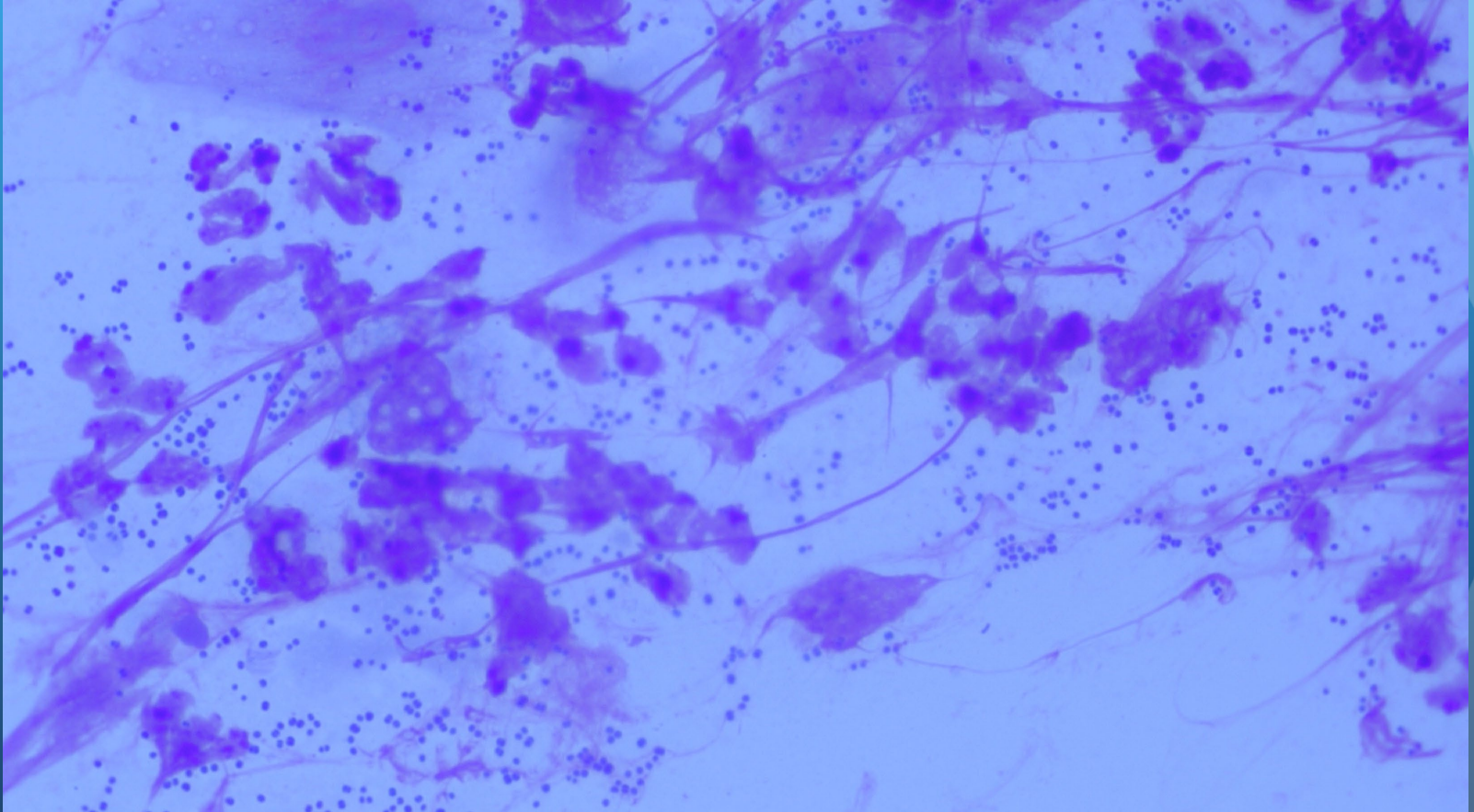


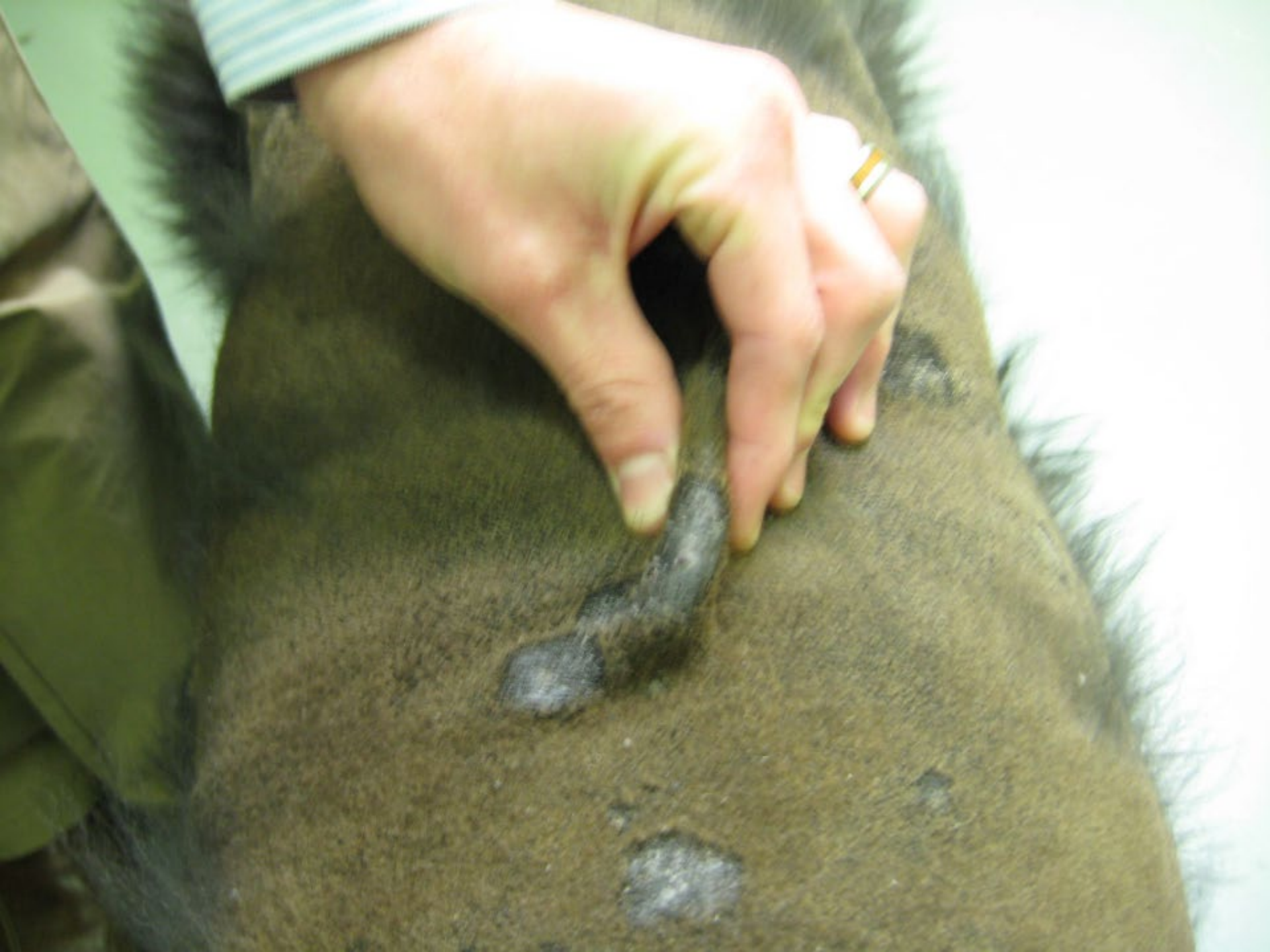**LIGHTHOUSE**

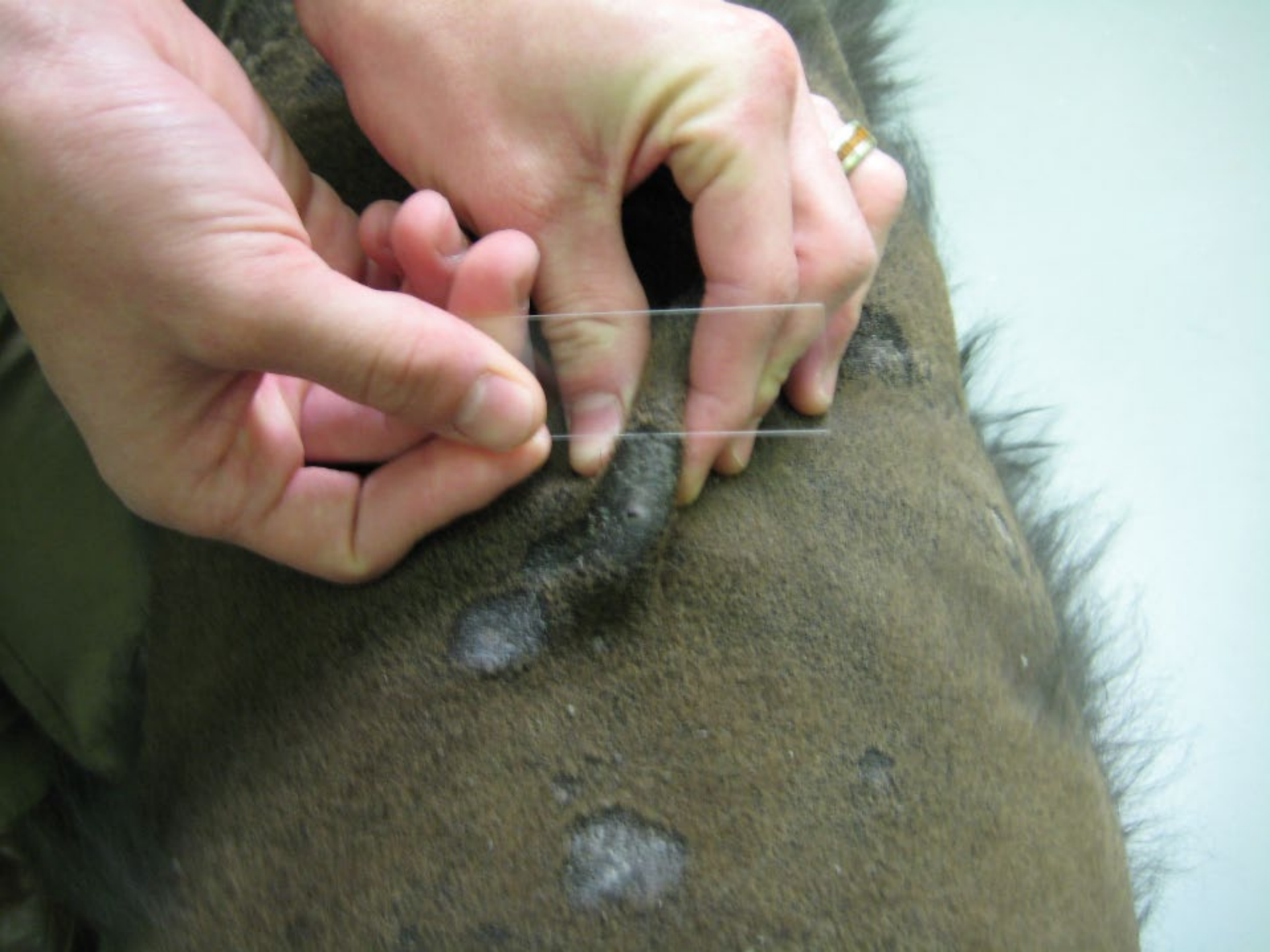— Veterinary Allergy & Dermatology —

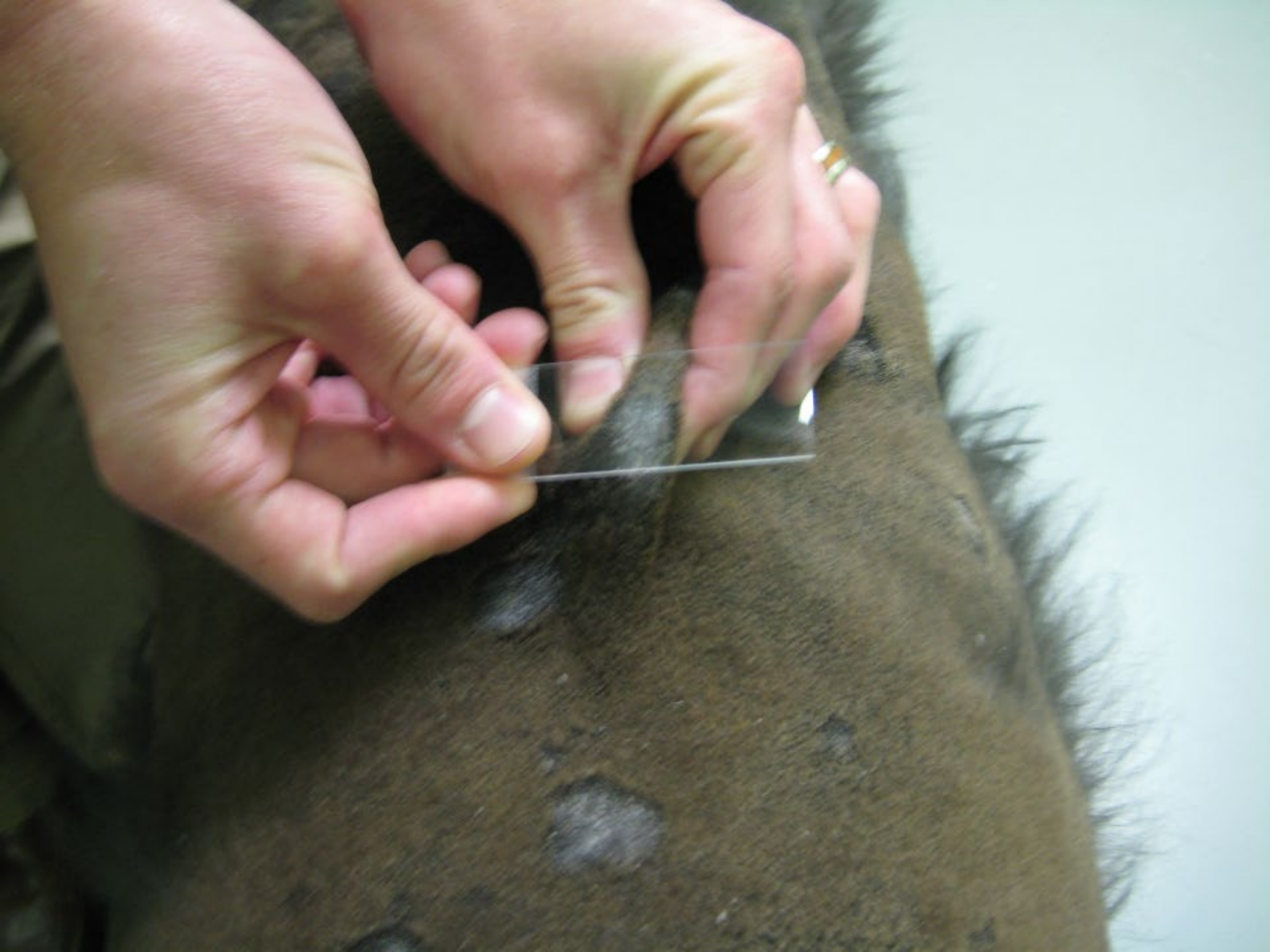

# Pyoderma

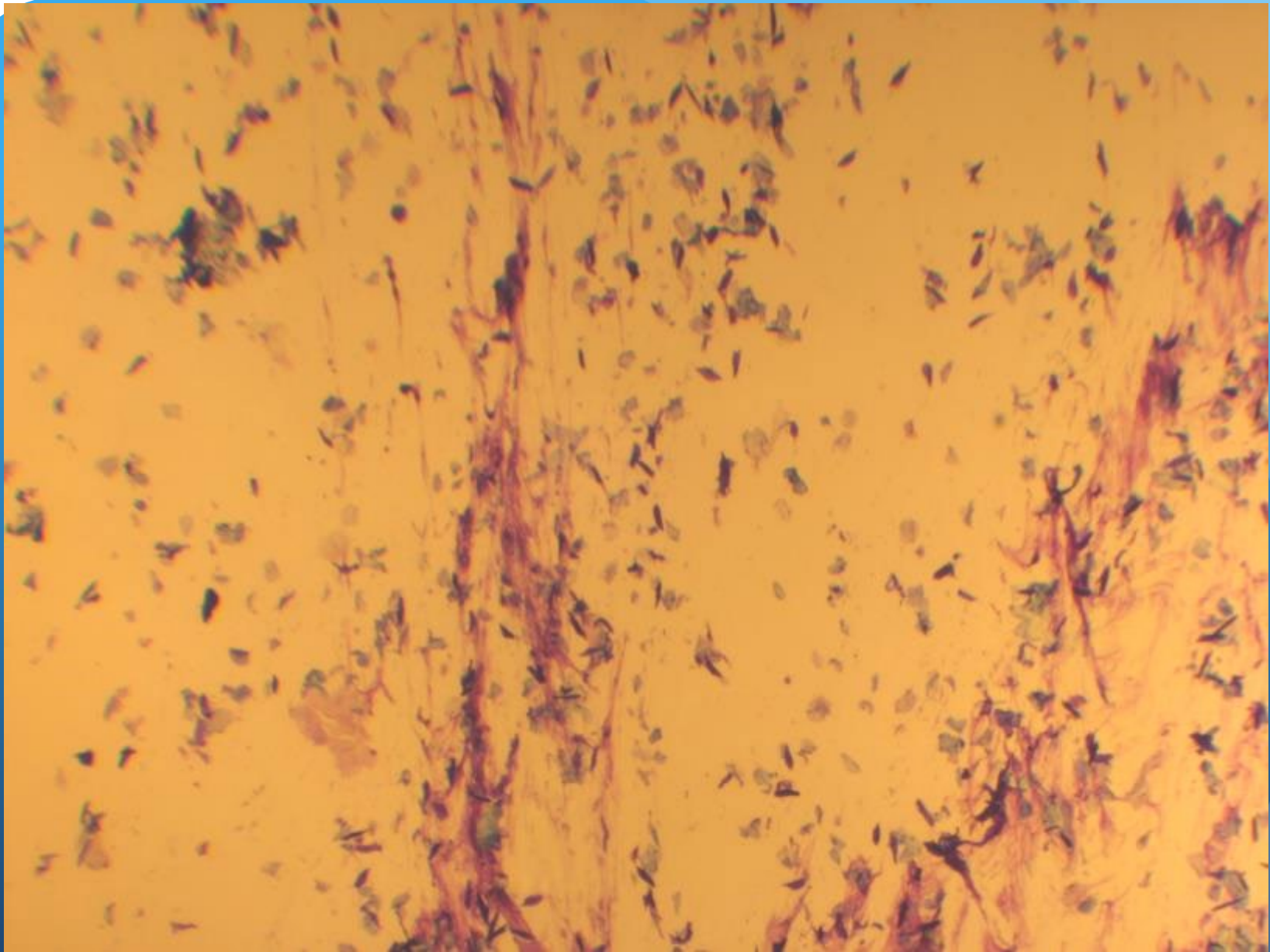


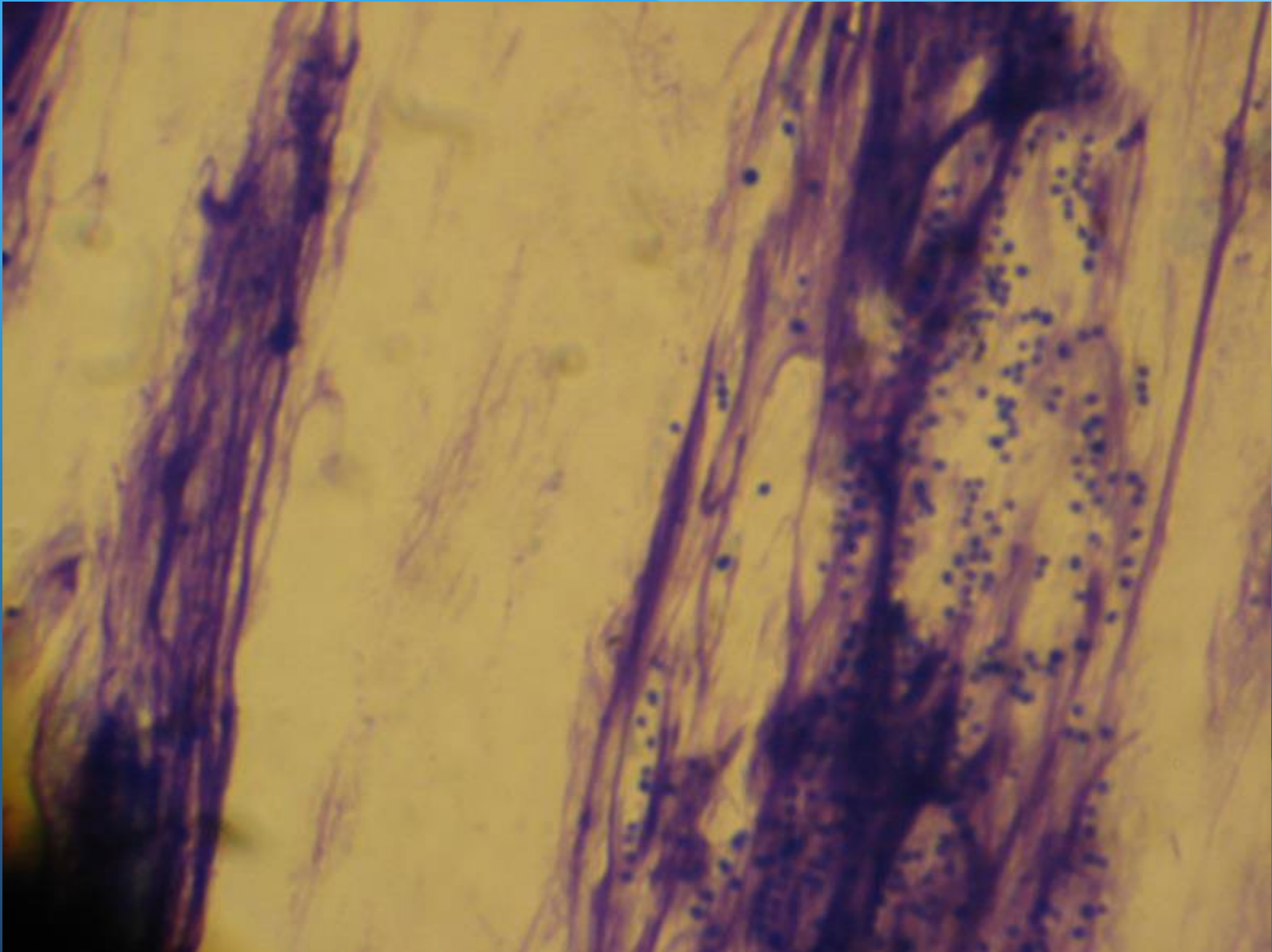


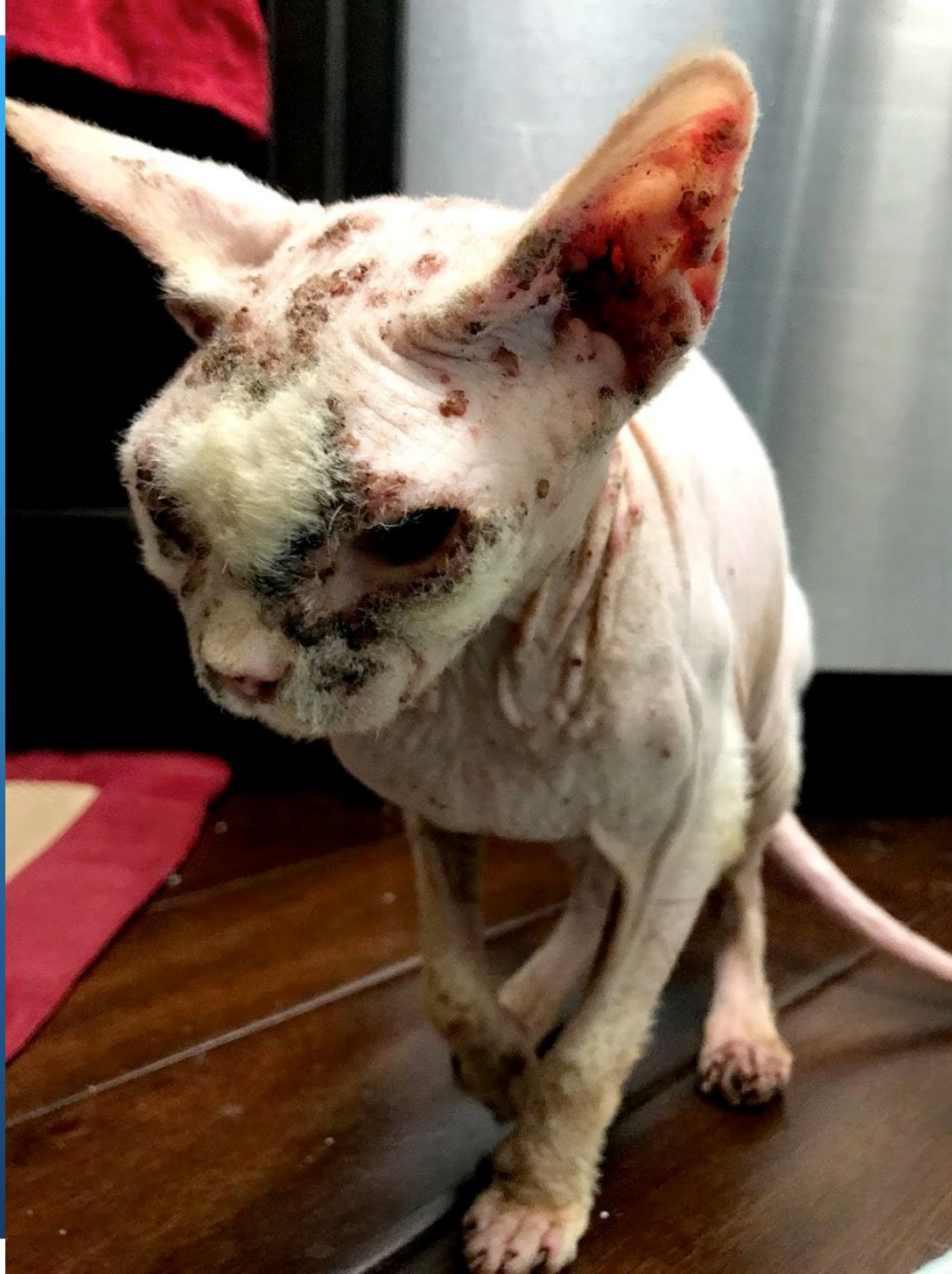





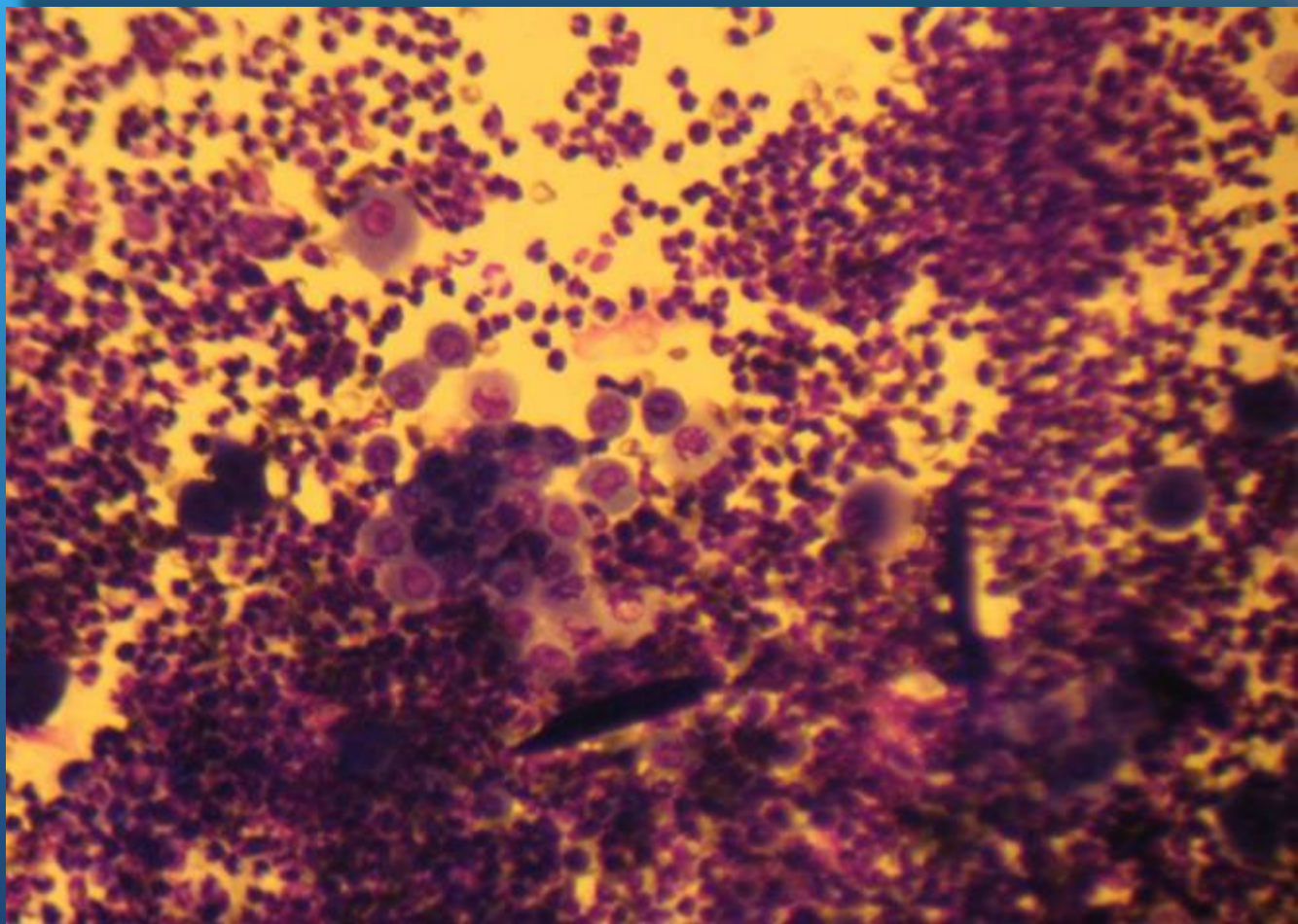




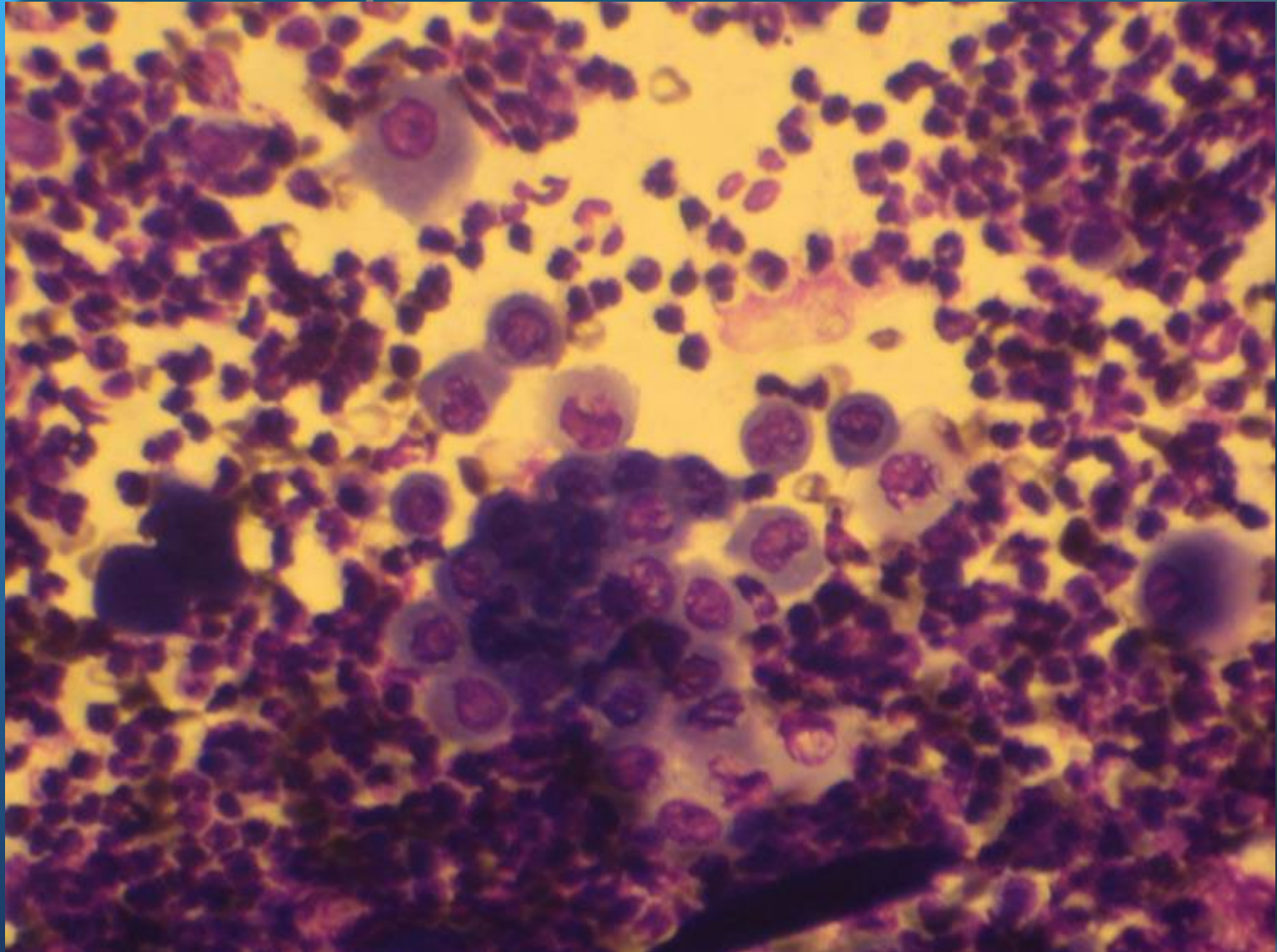




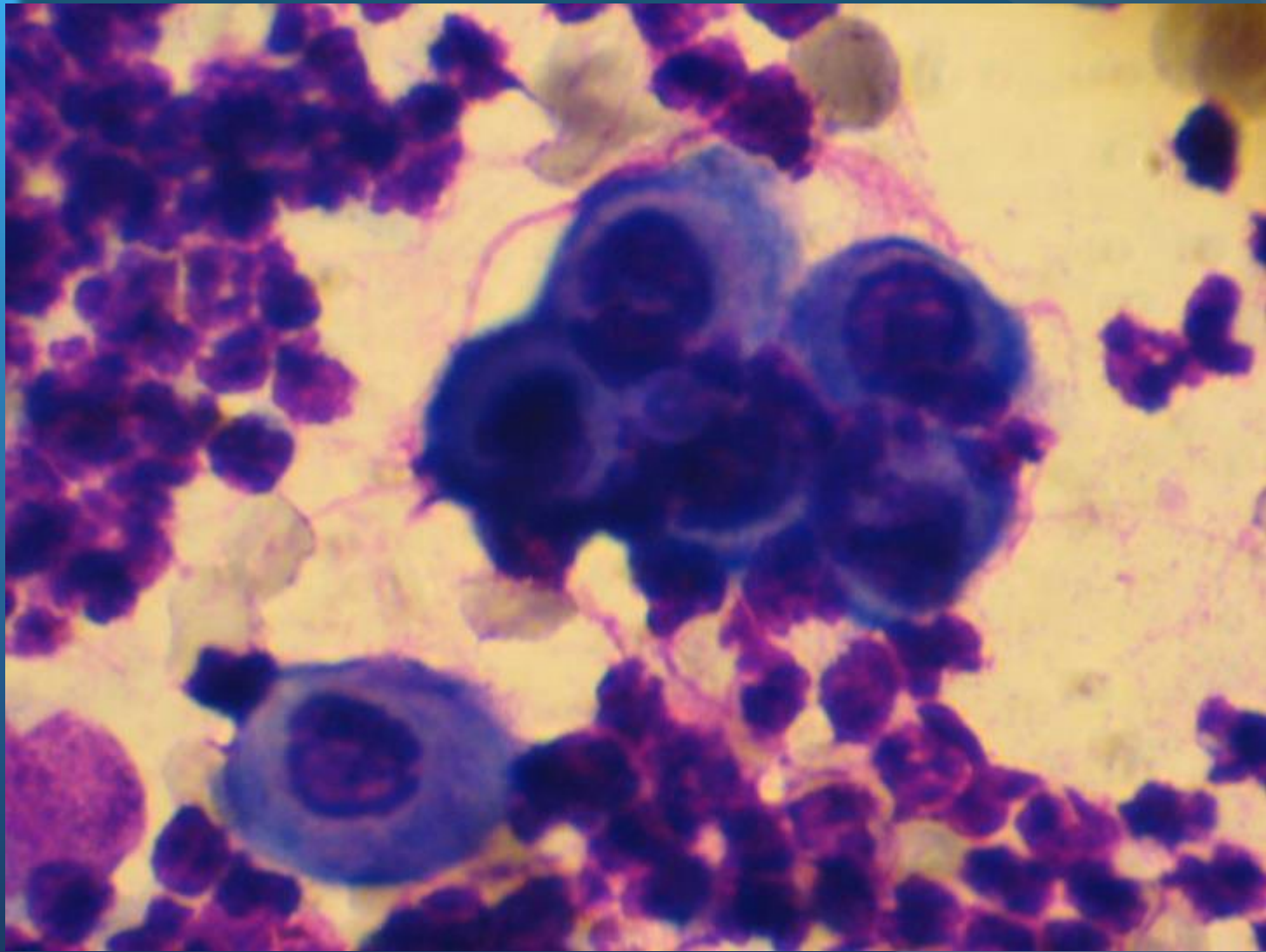
# Keratinocytes

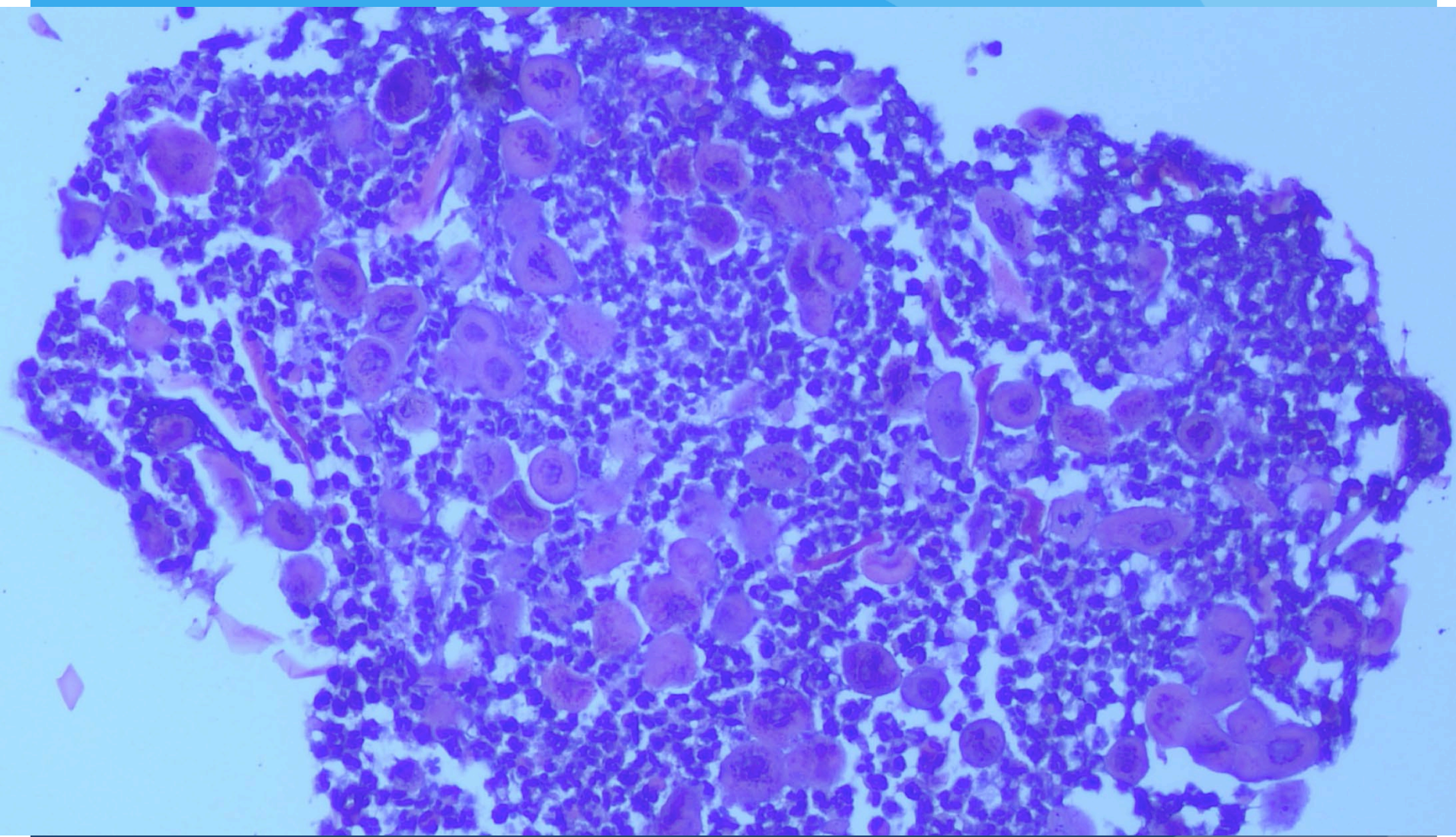


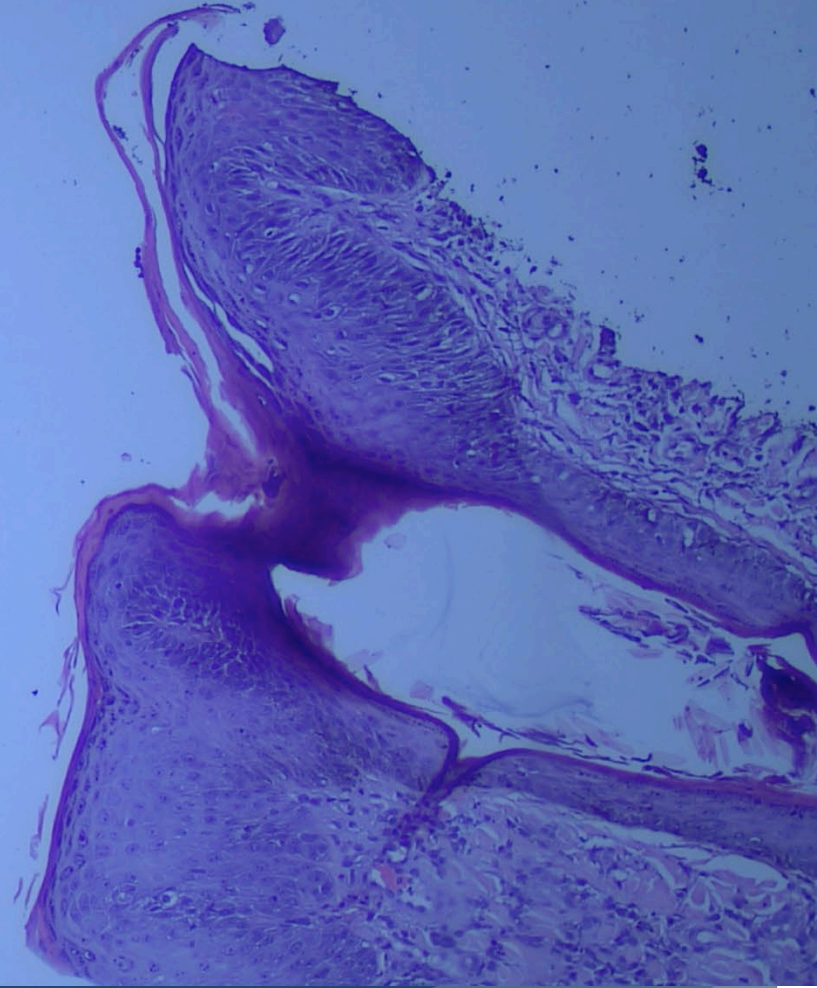
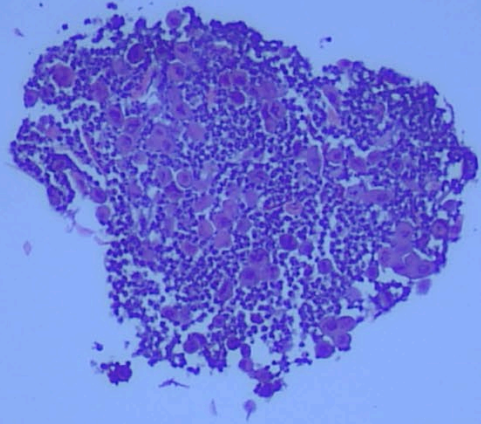
# Keratinocytes

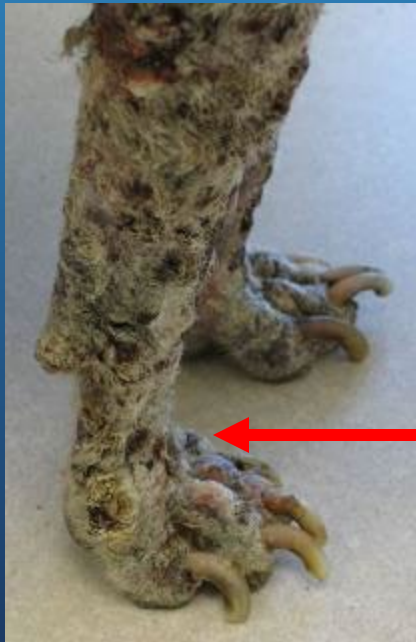
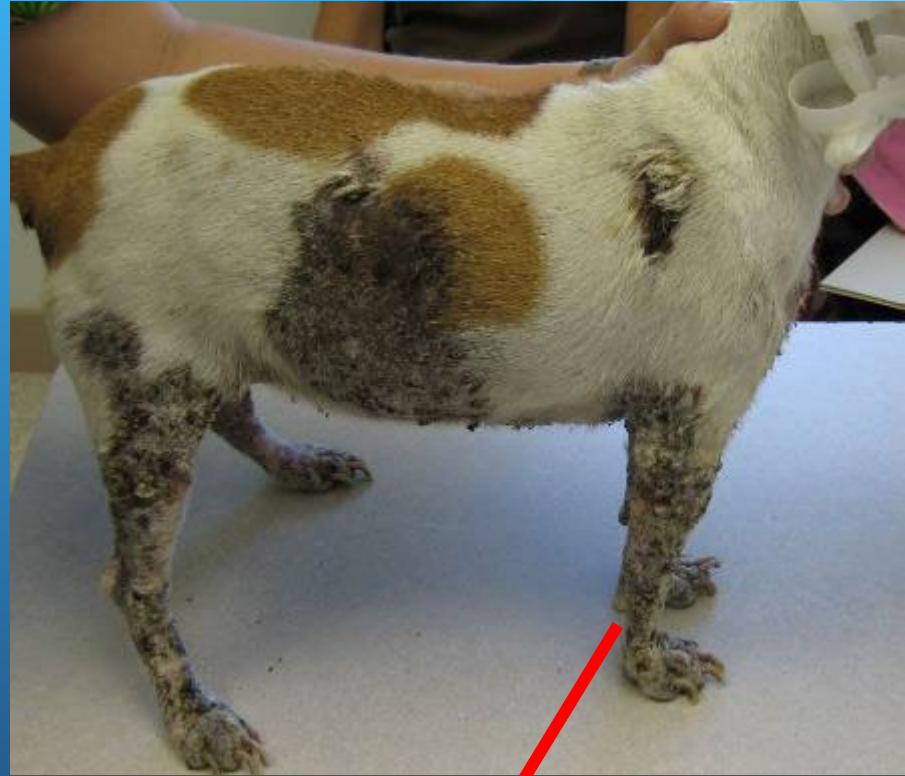
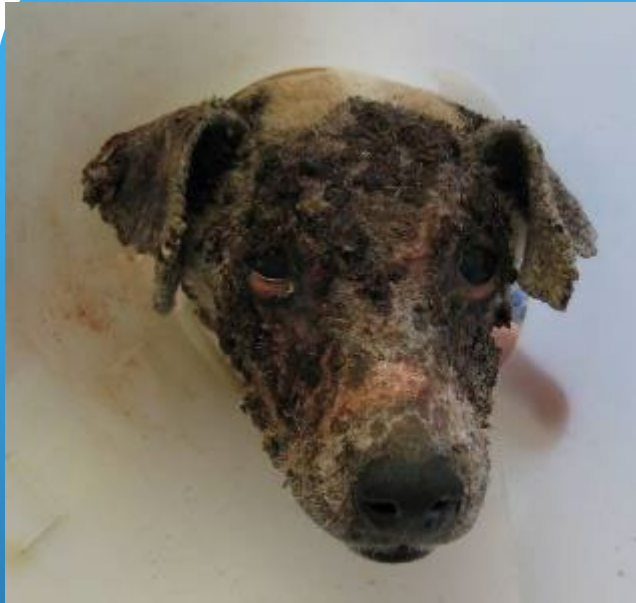# Keratinocytes

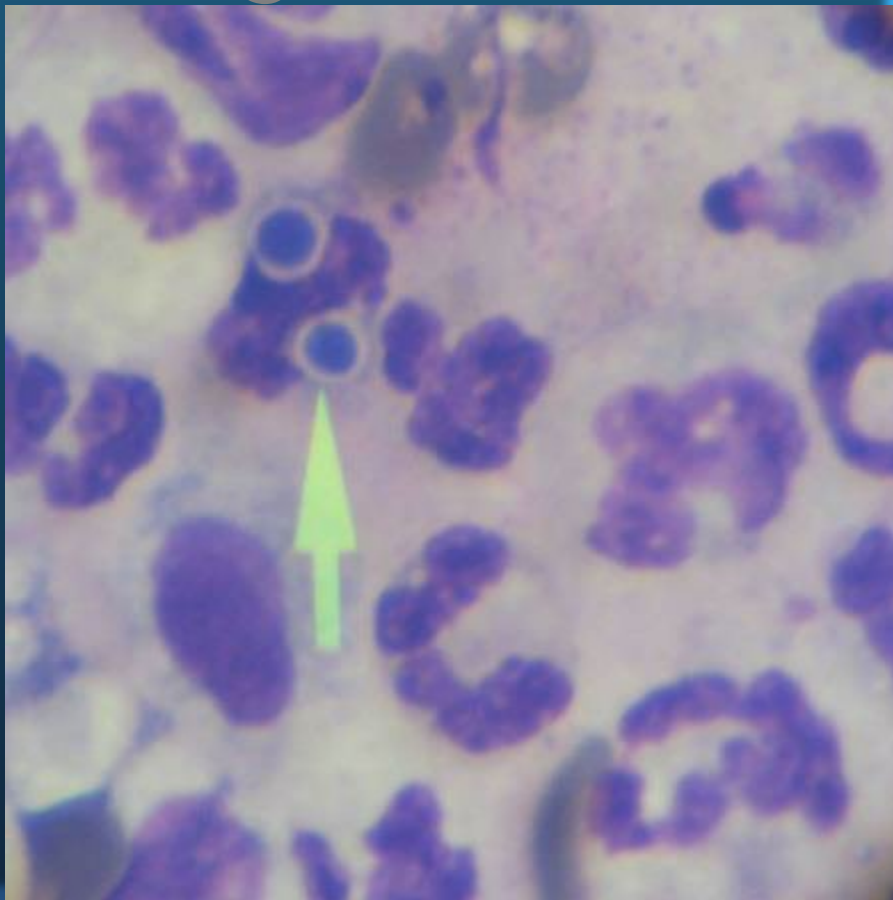




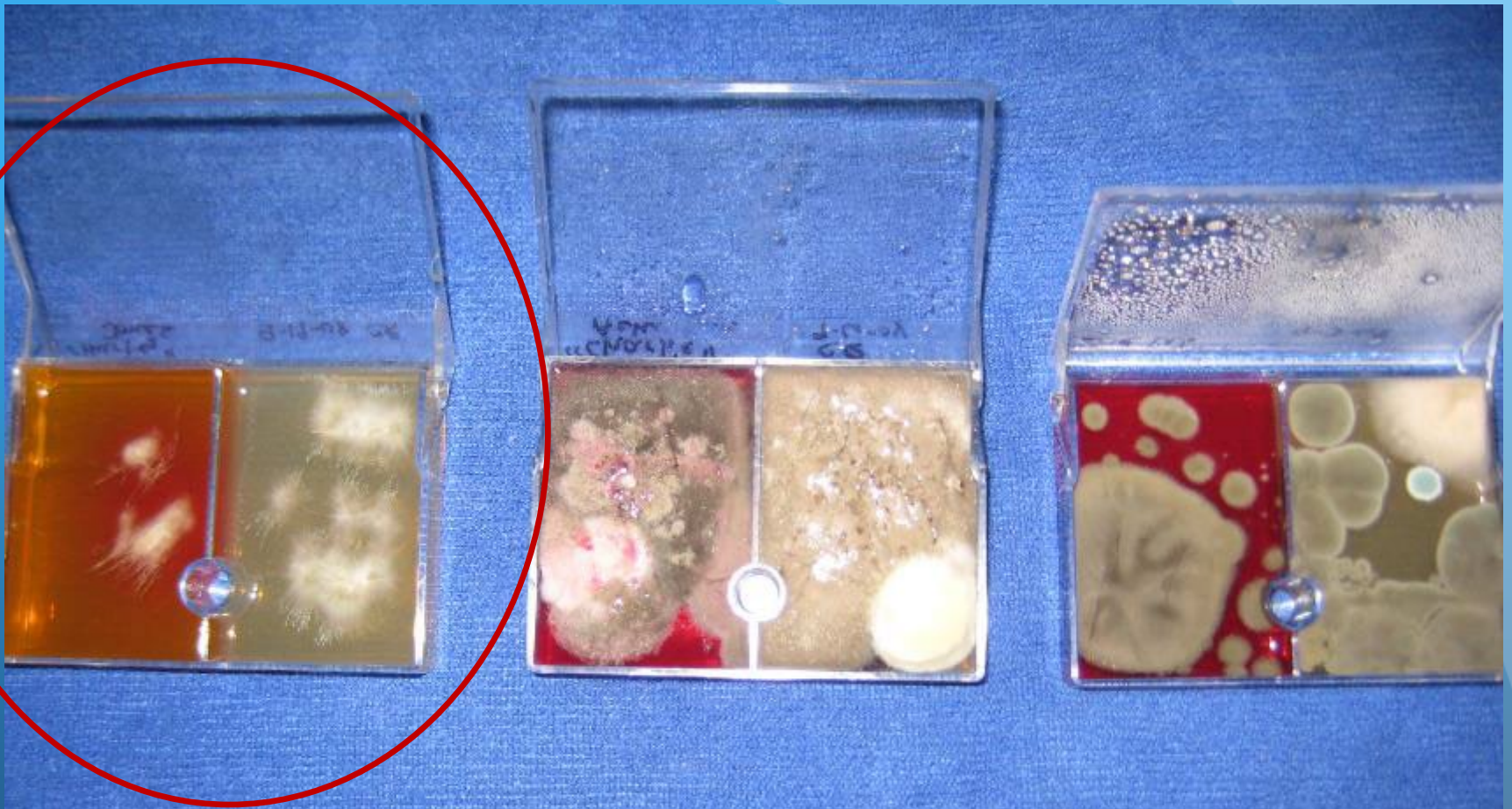



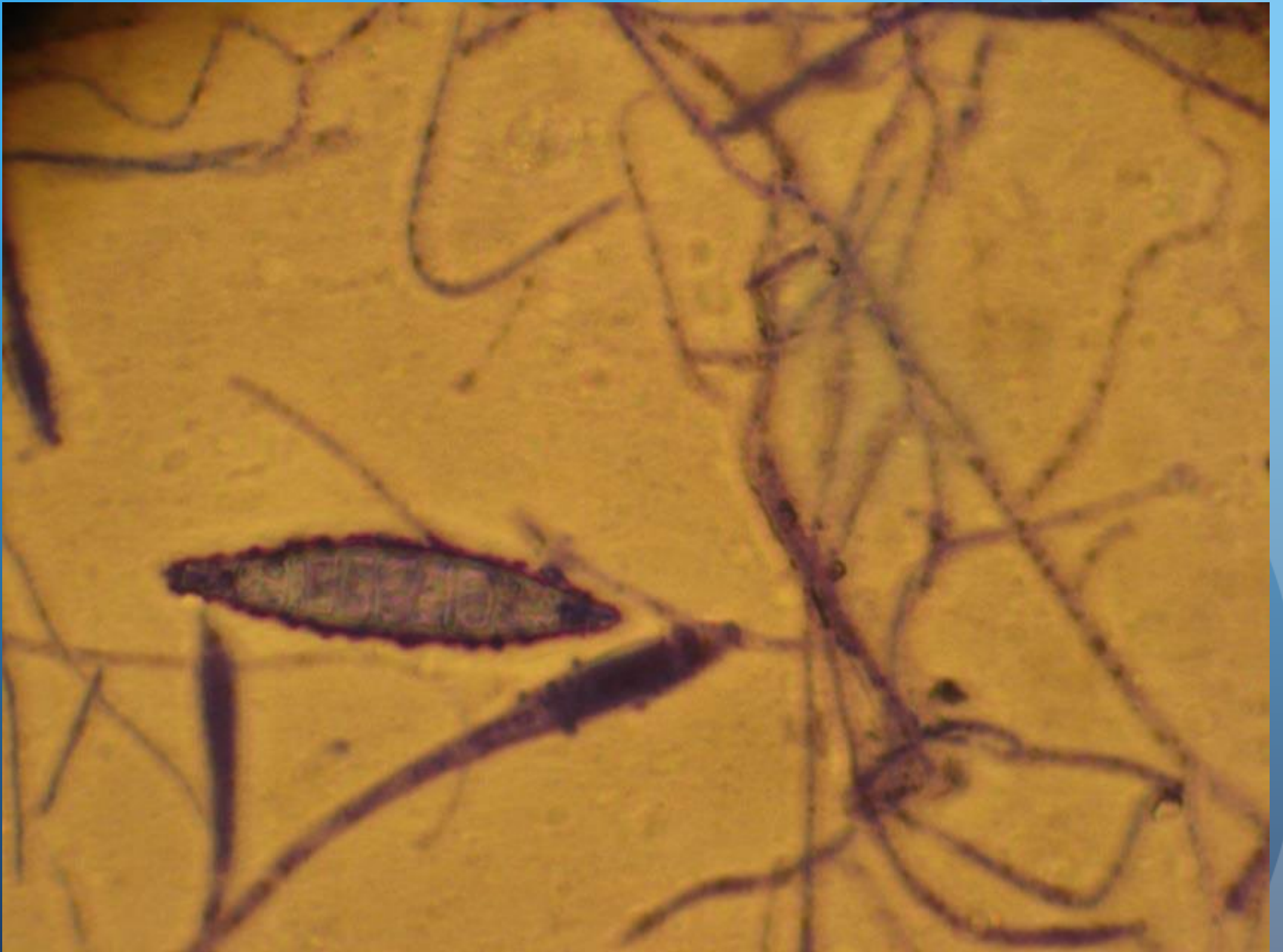# Fungi

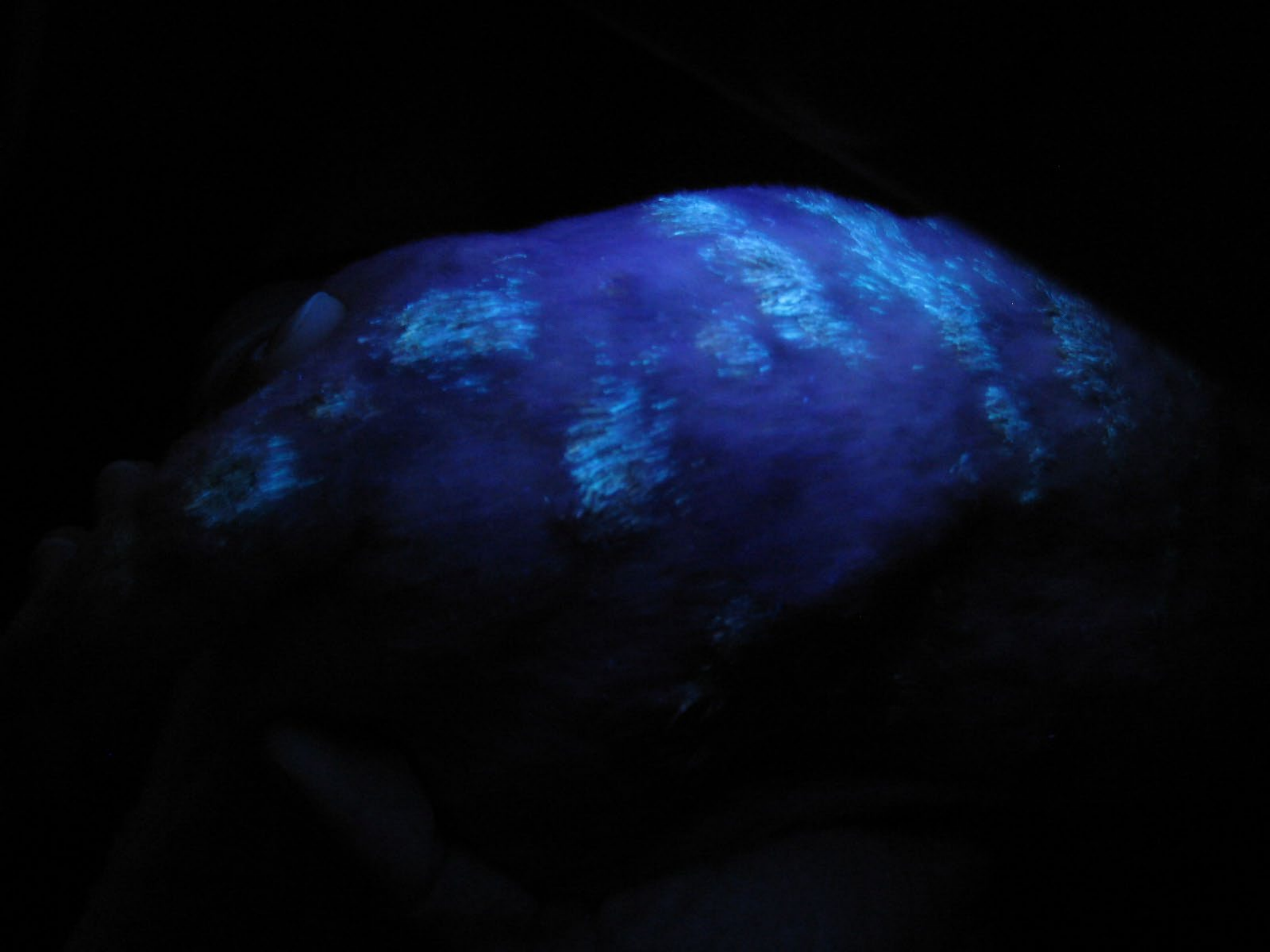


Fungal spores within  
neutrophil

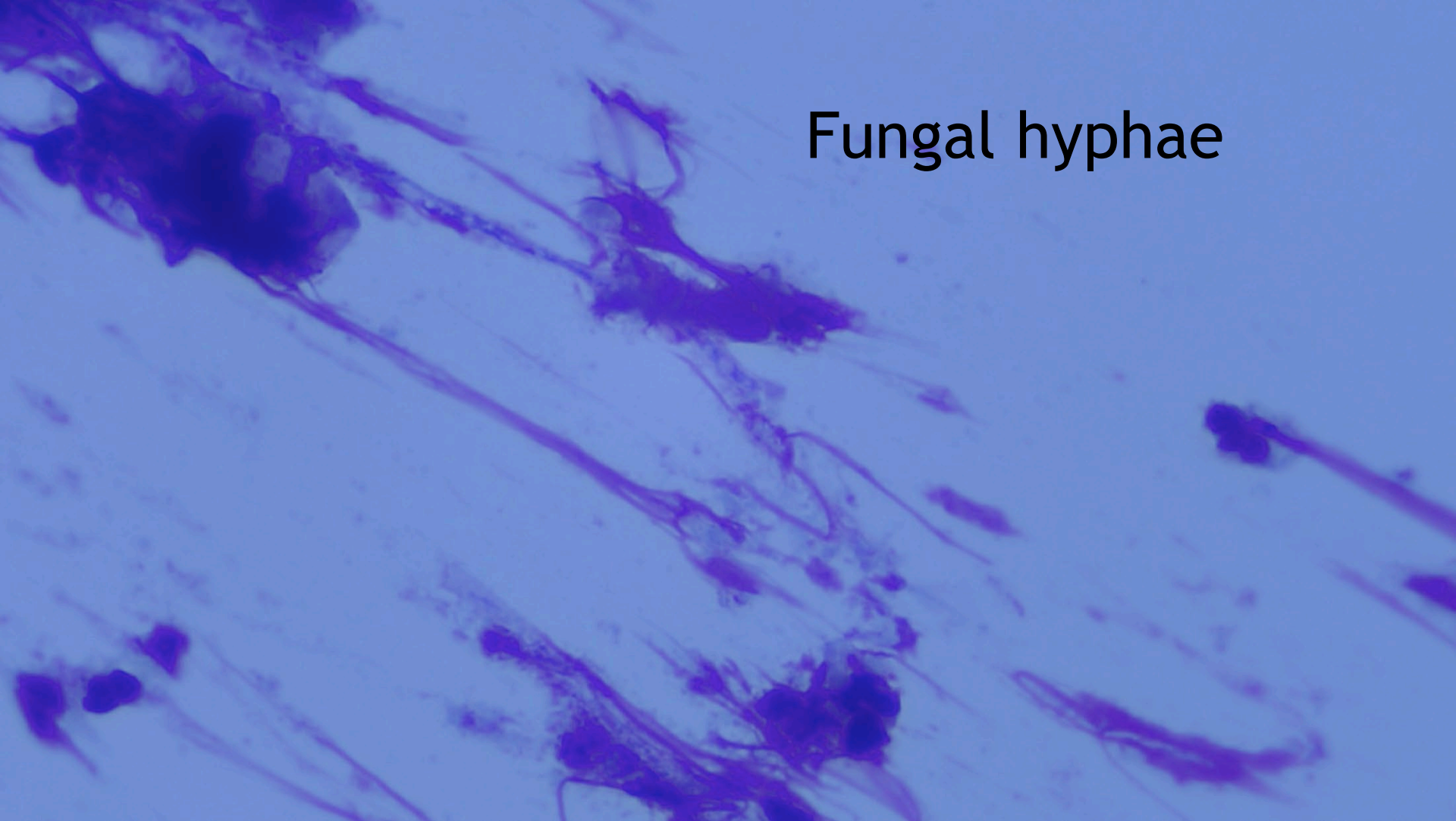


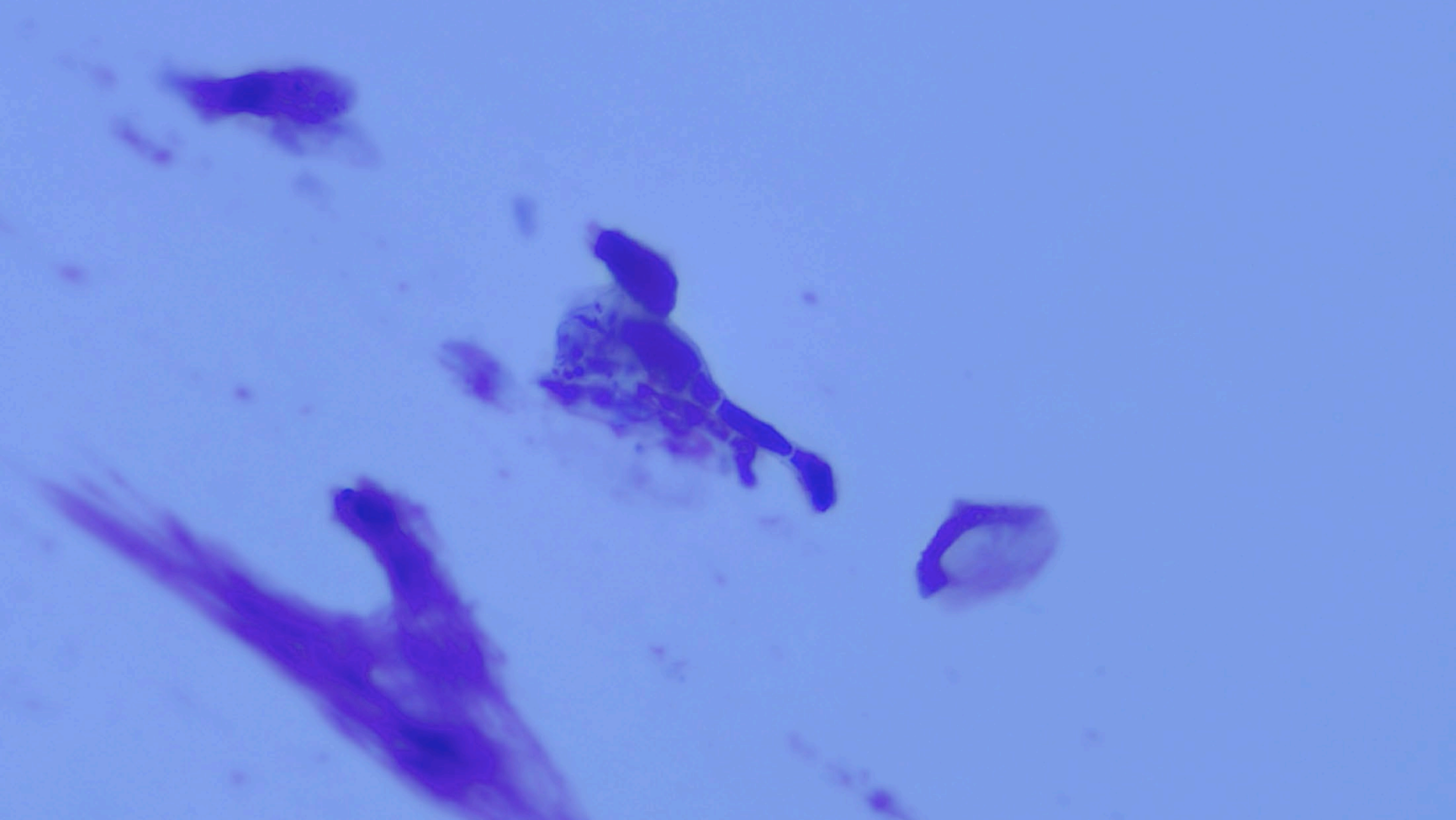
Which one is the dermatophyte???

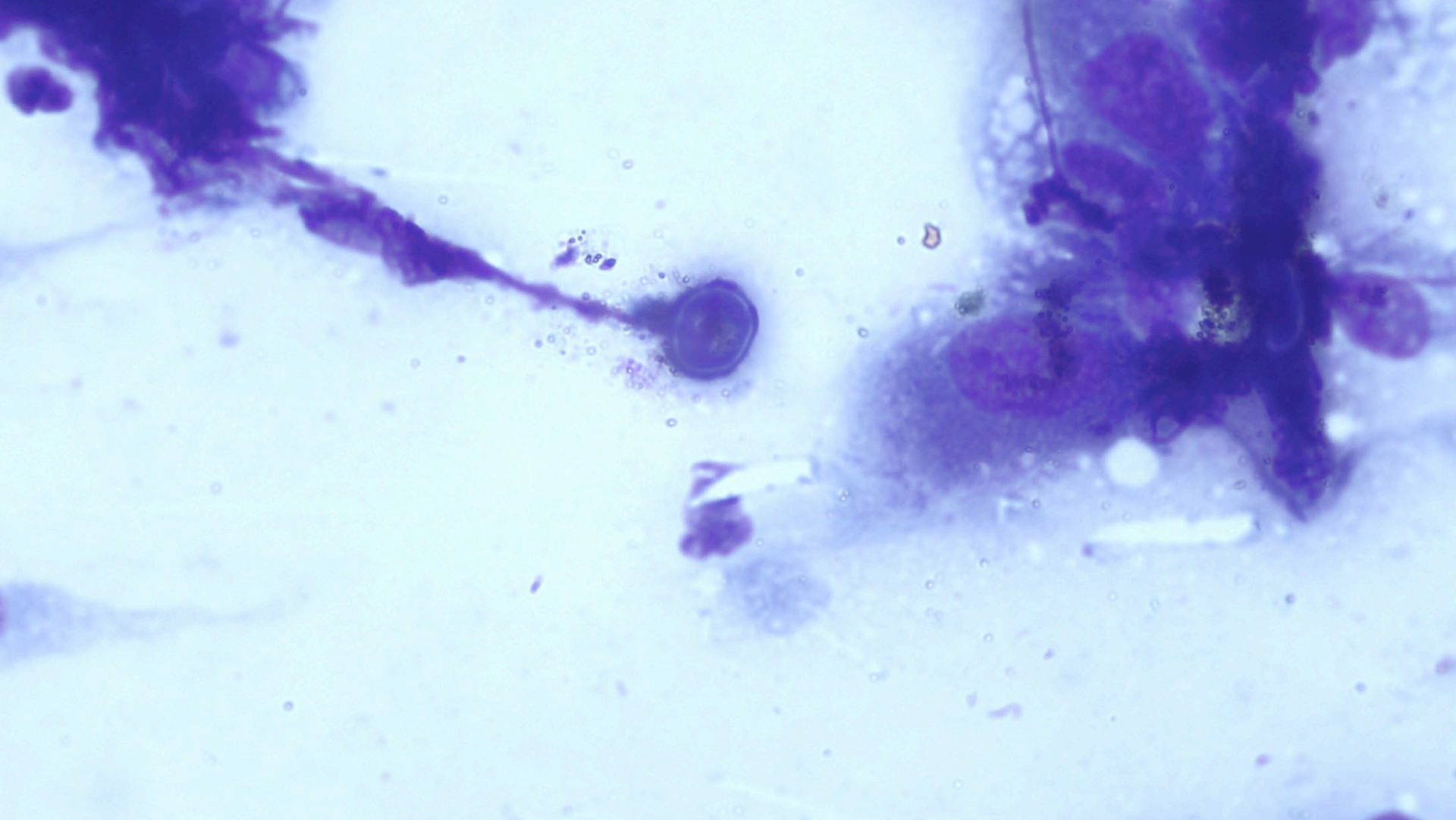


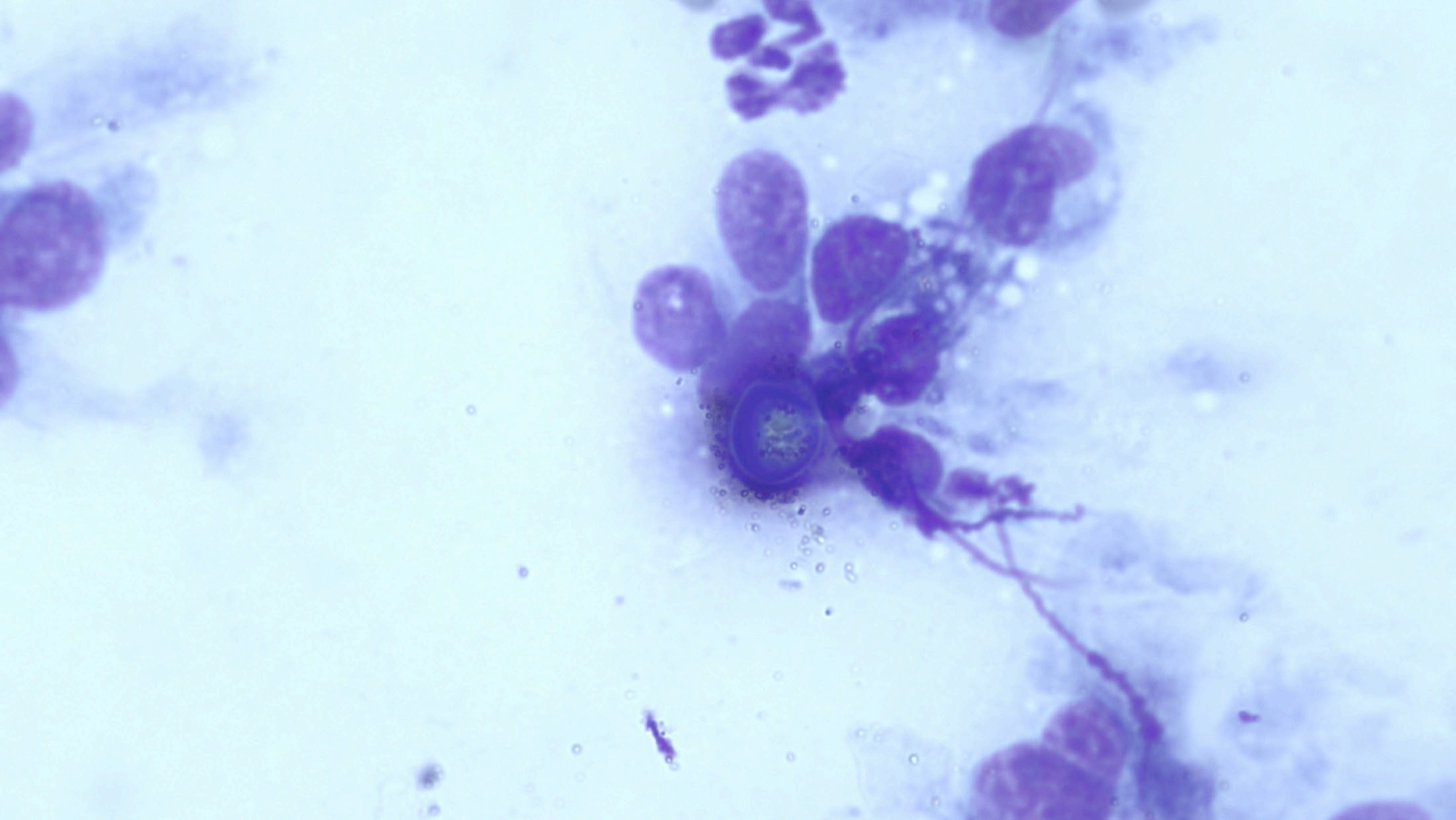


# Fungal hyphae

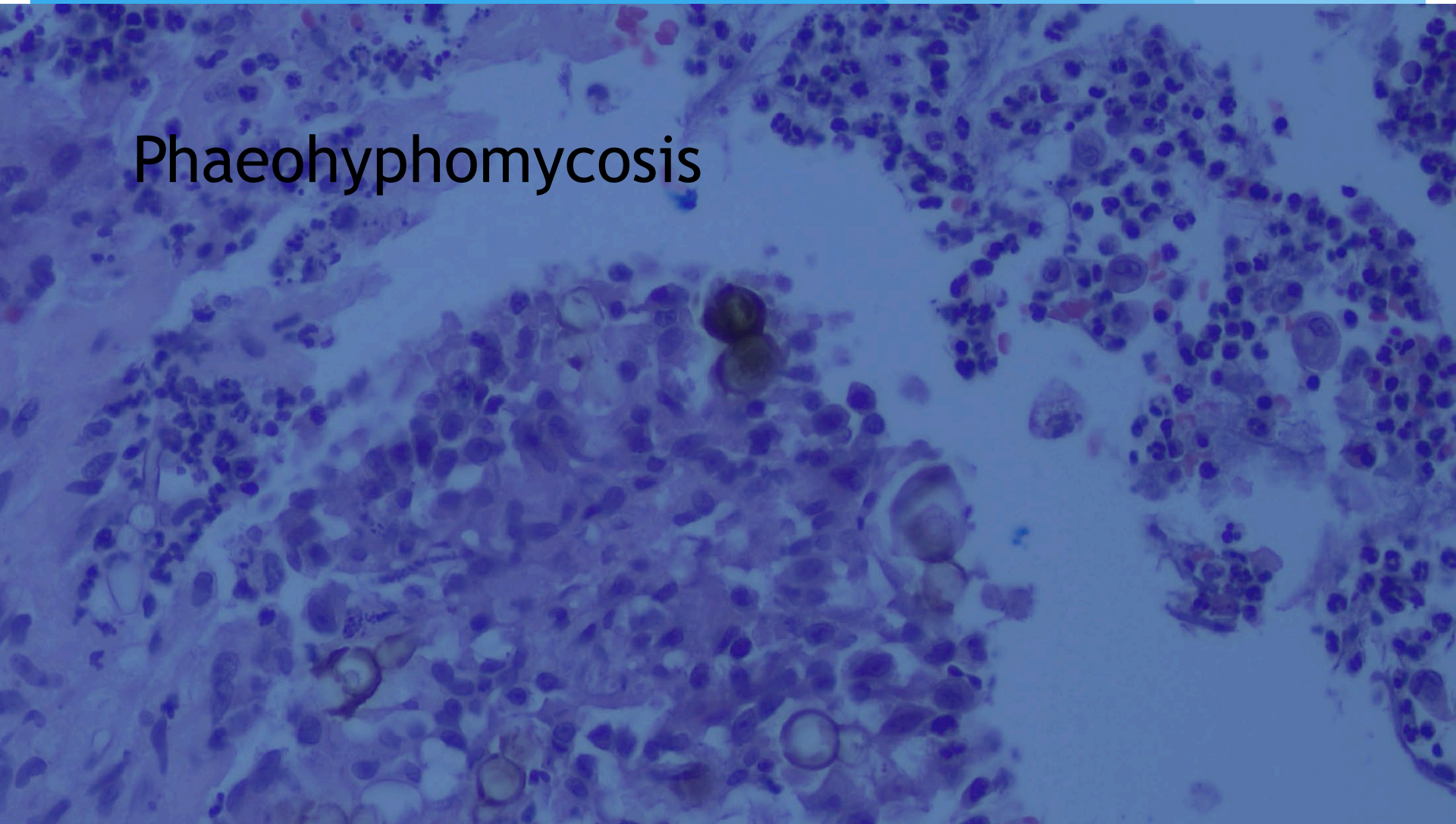


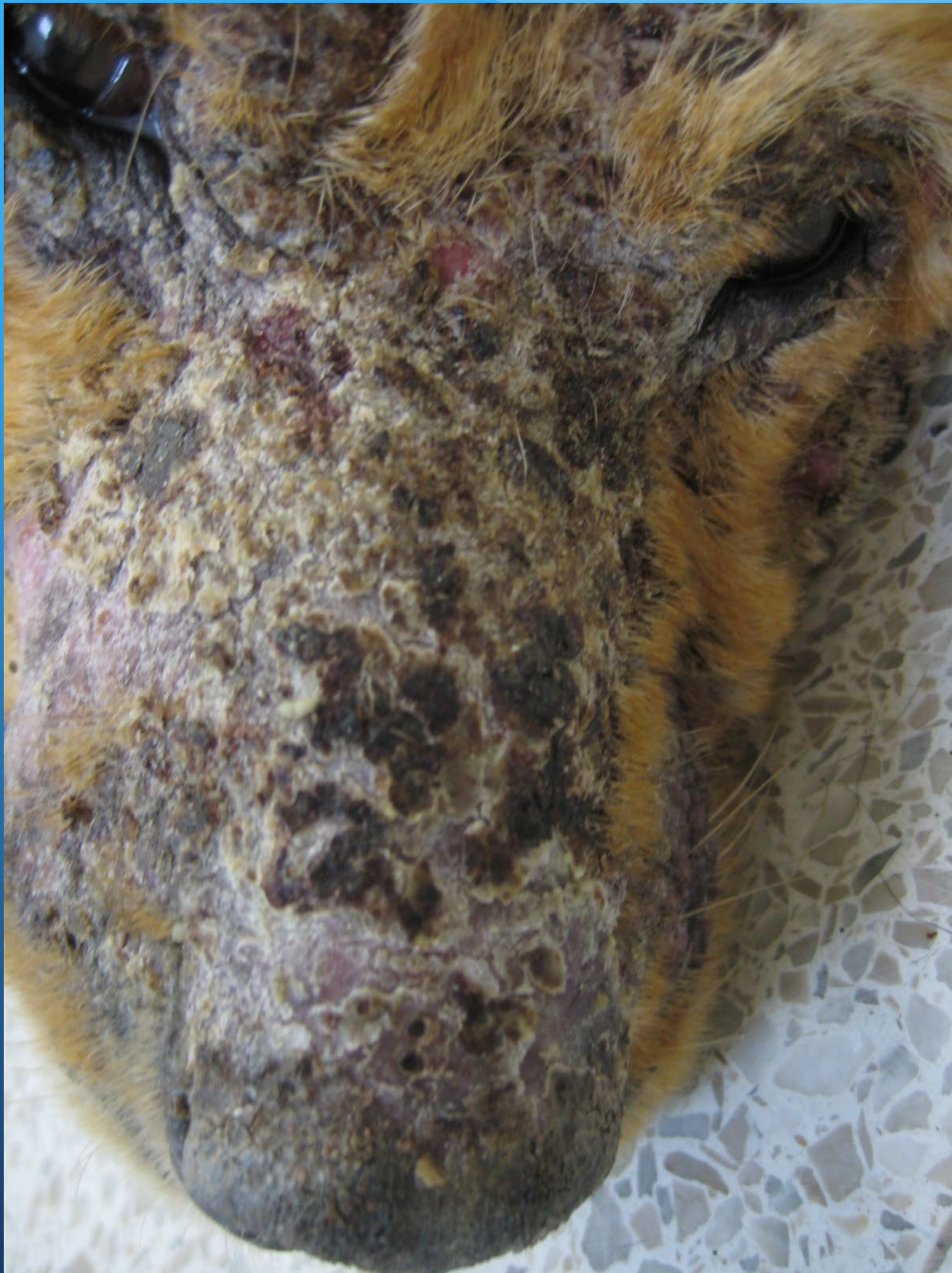


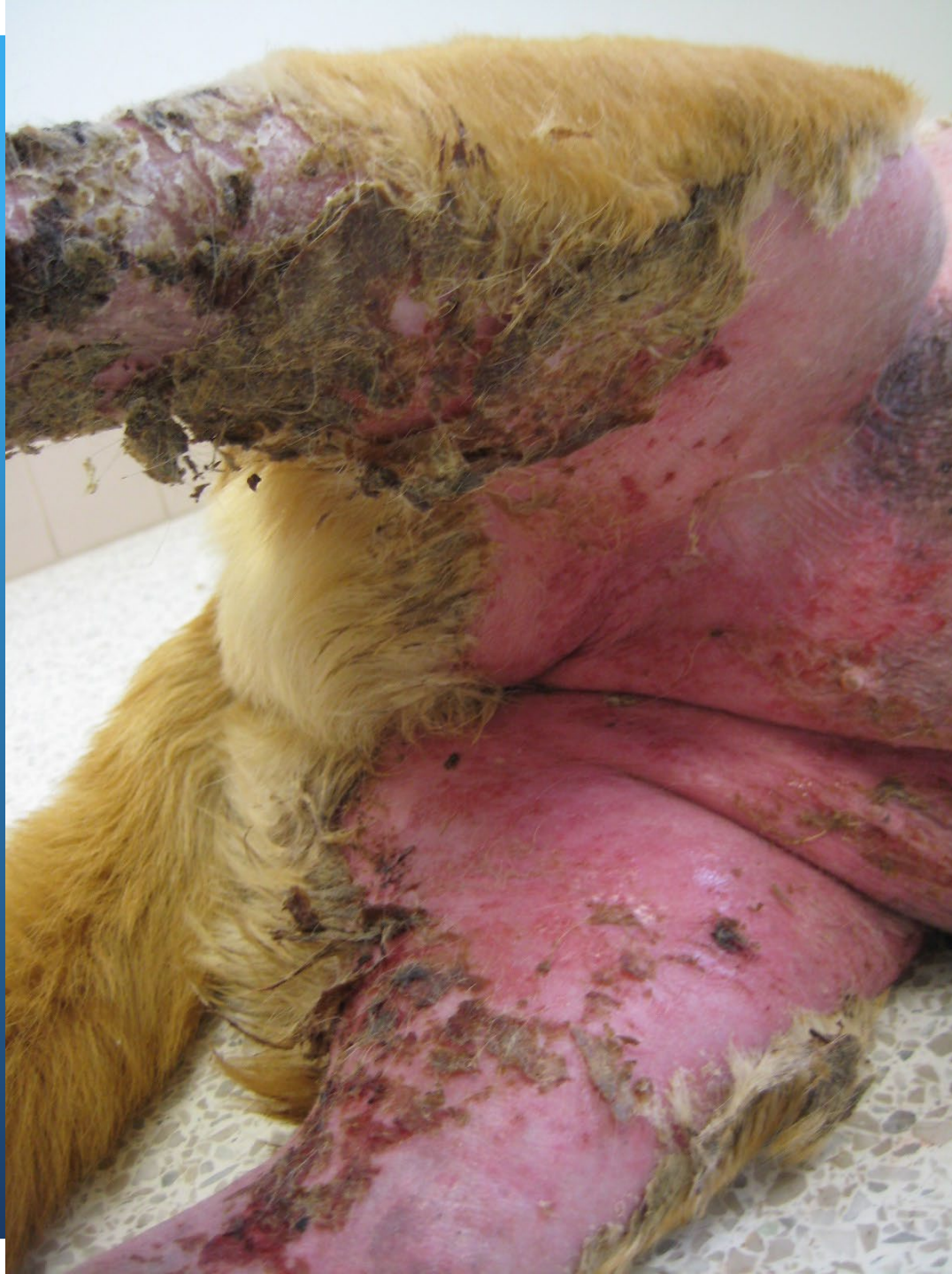


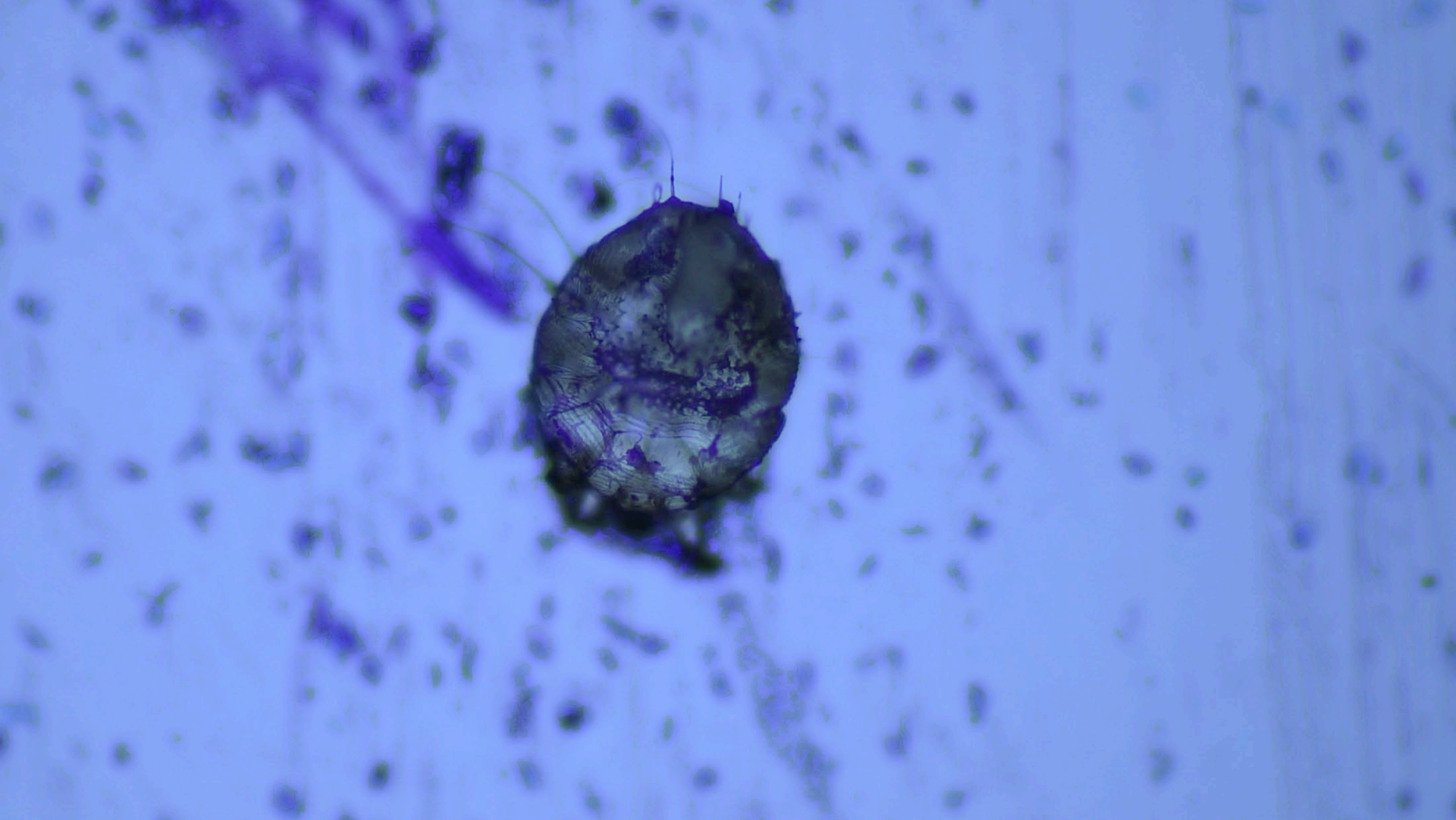
# Phaeohyphomycosis



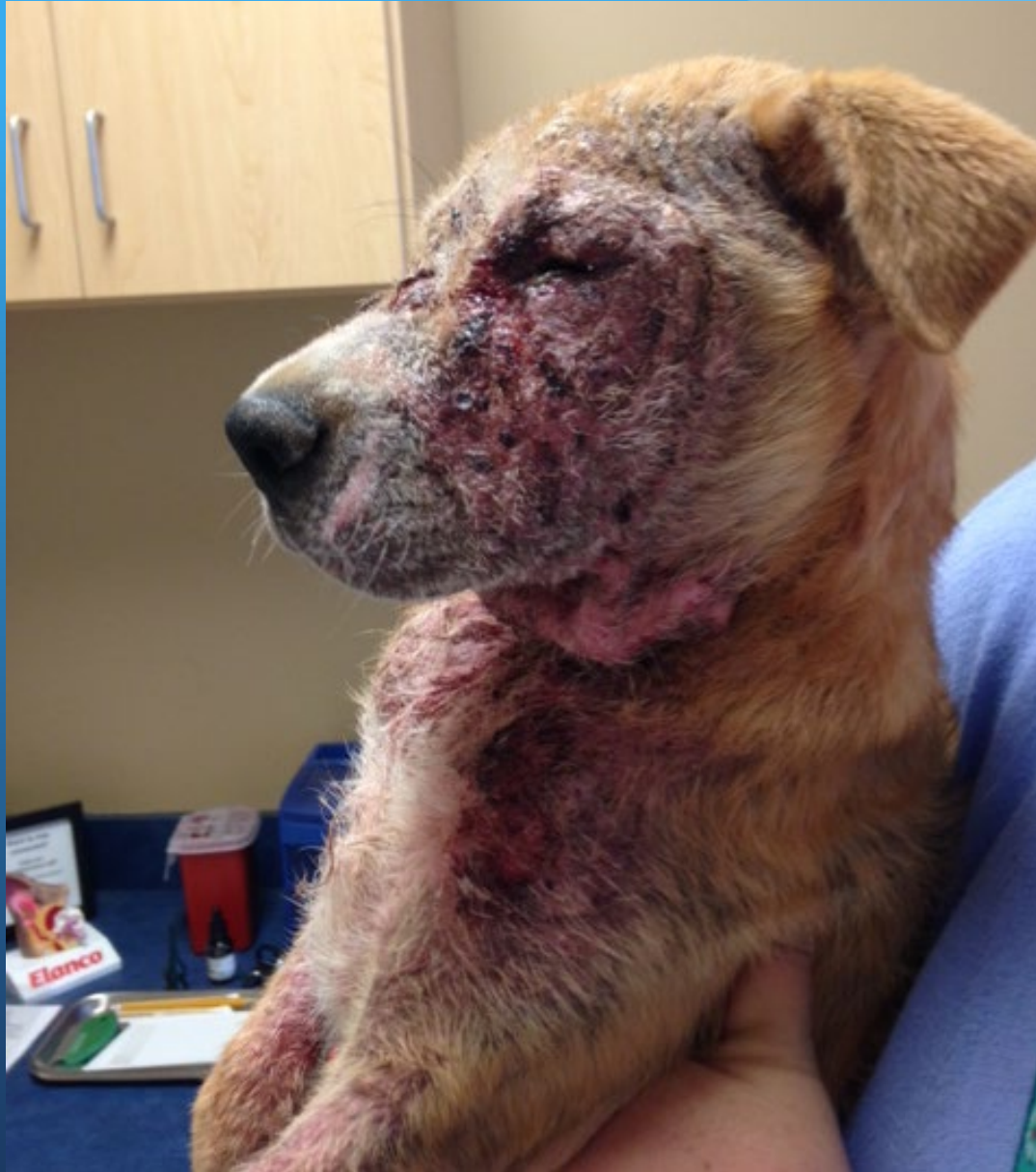



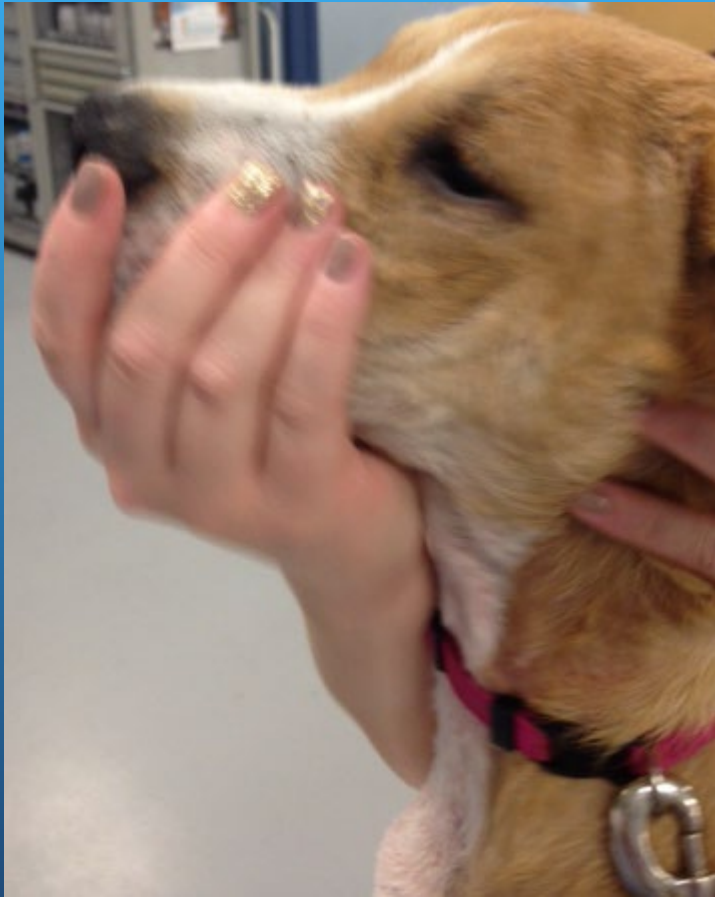


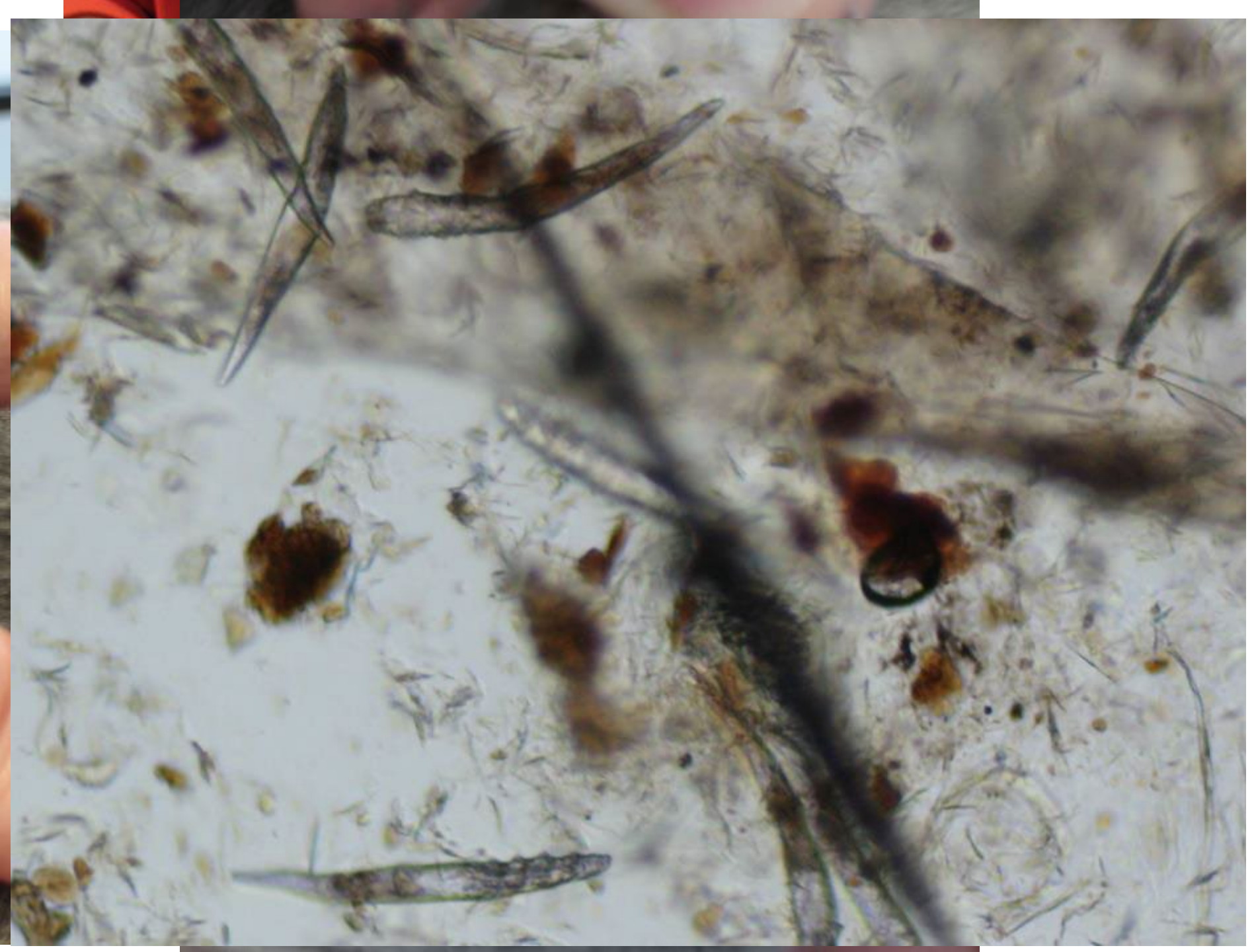


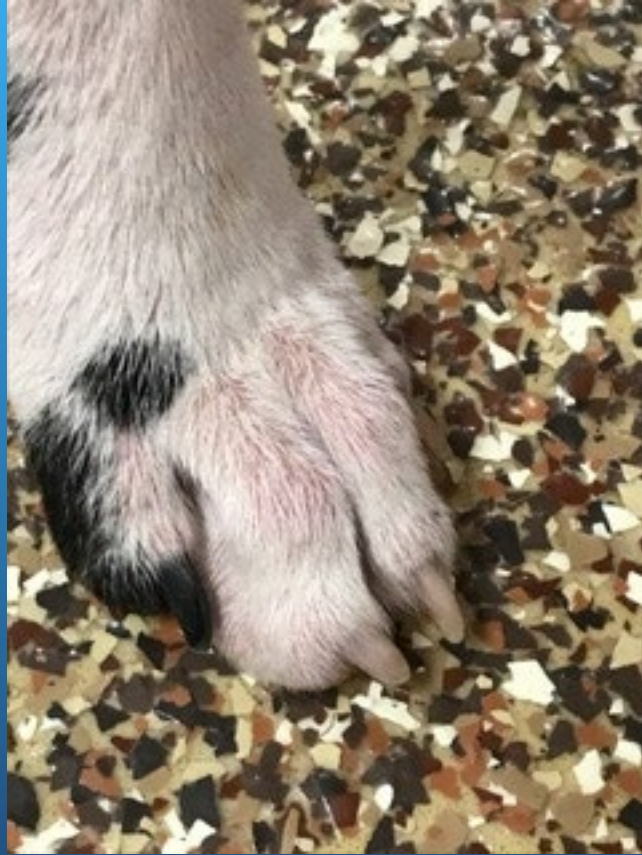BEFORE

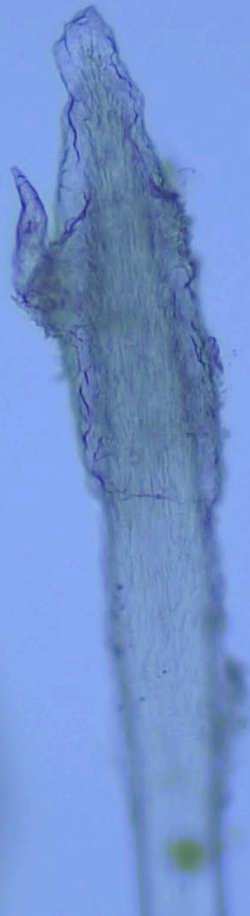


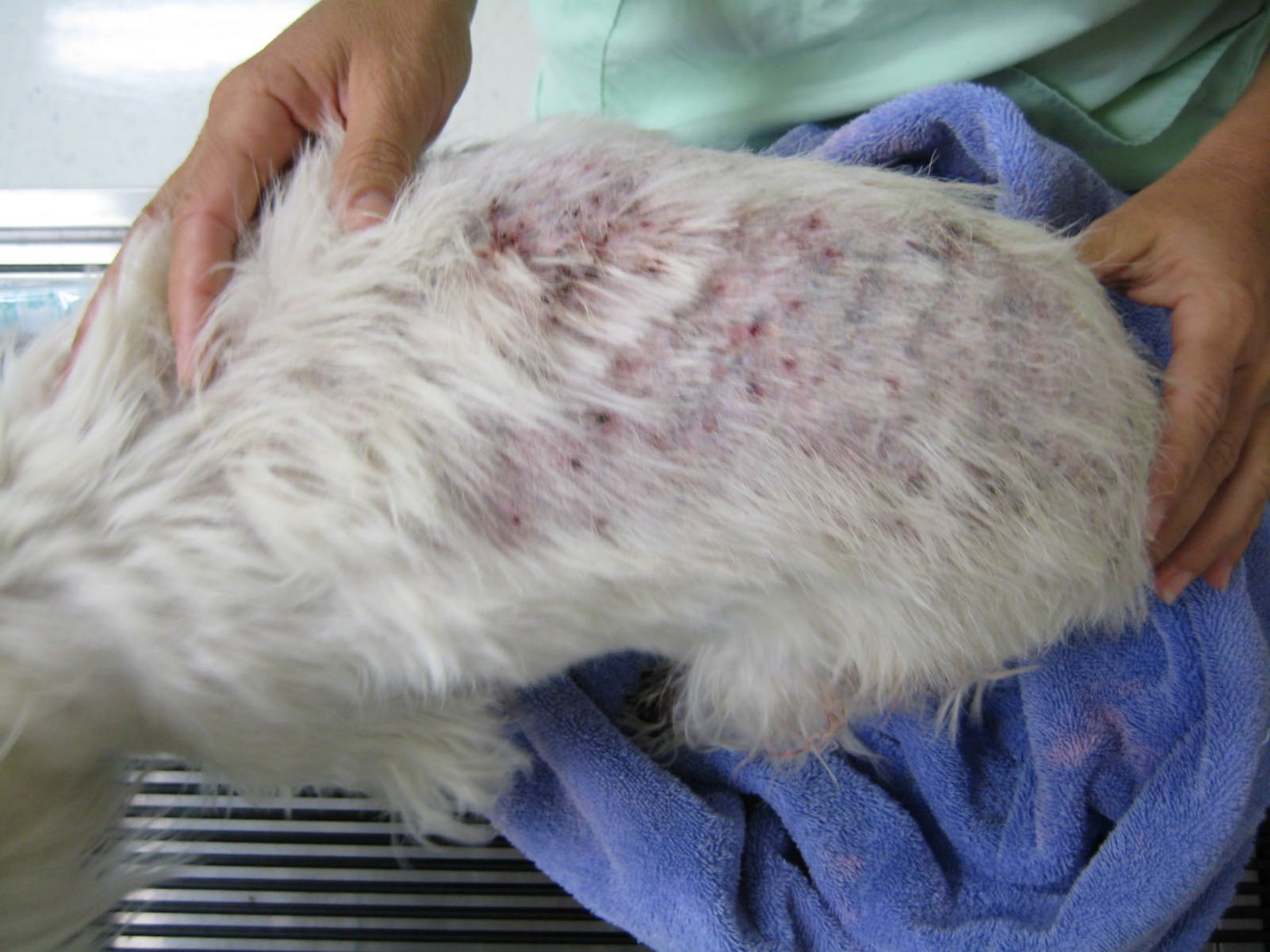AFTER

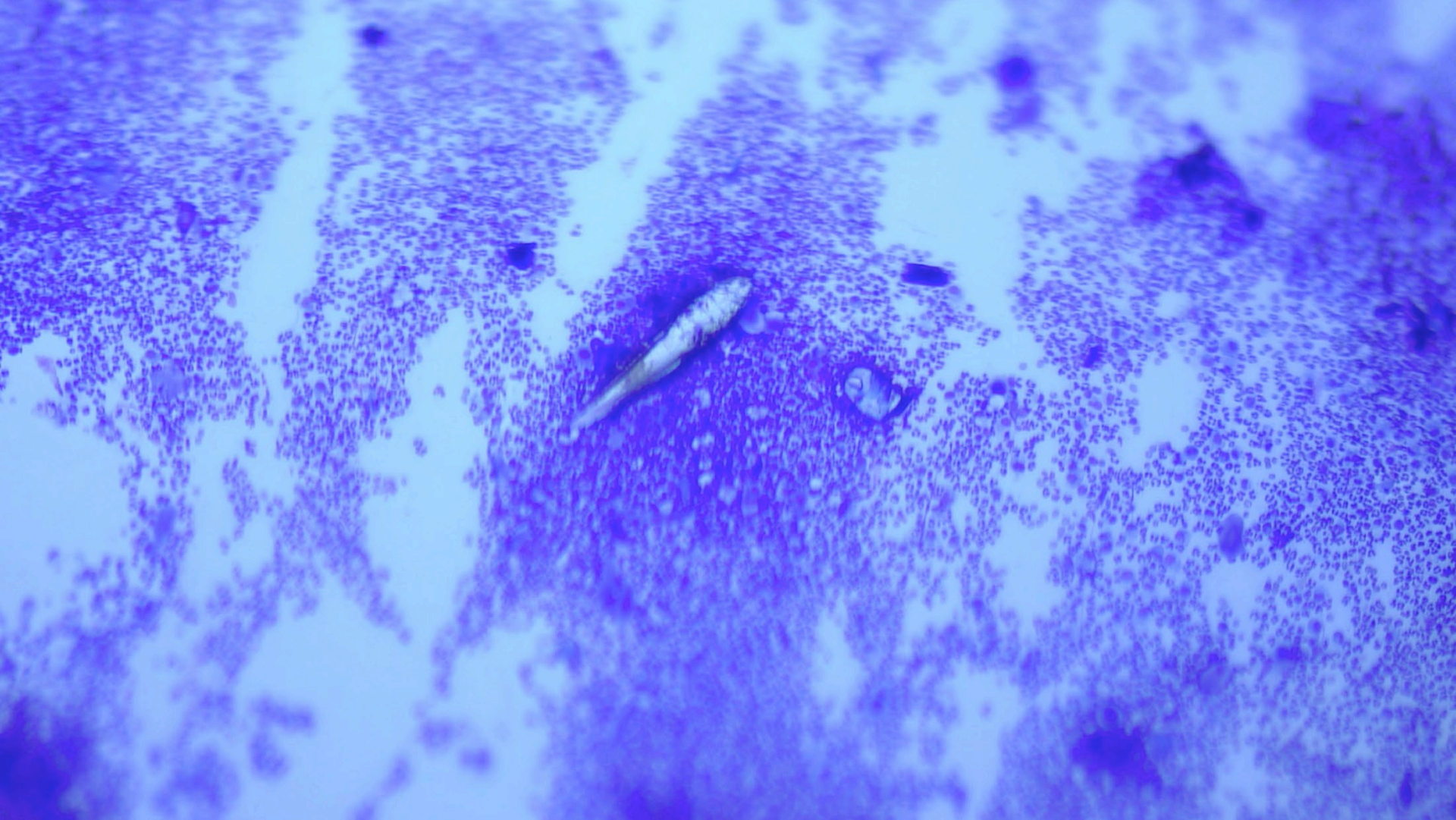


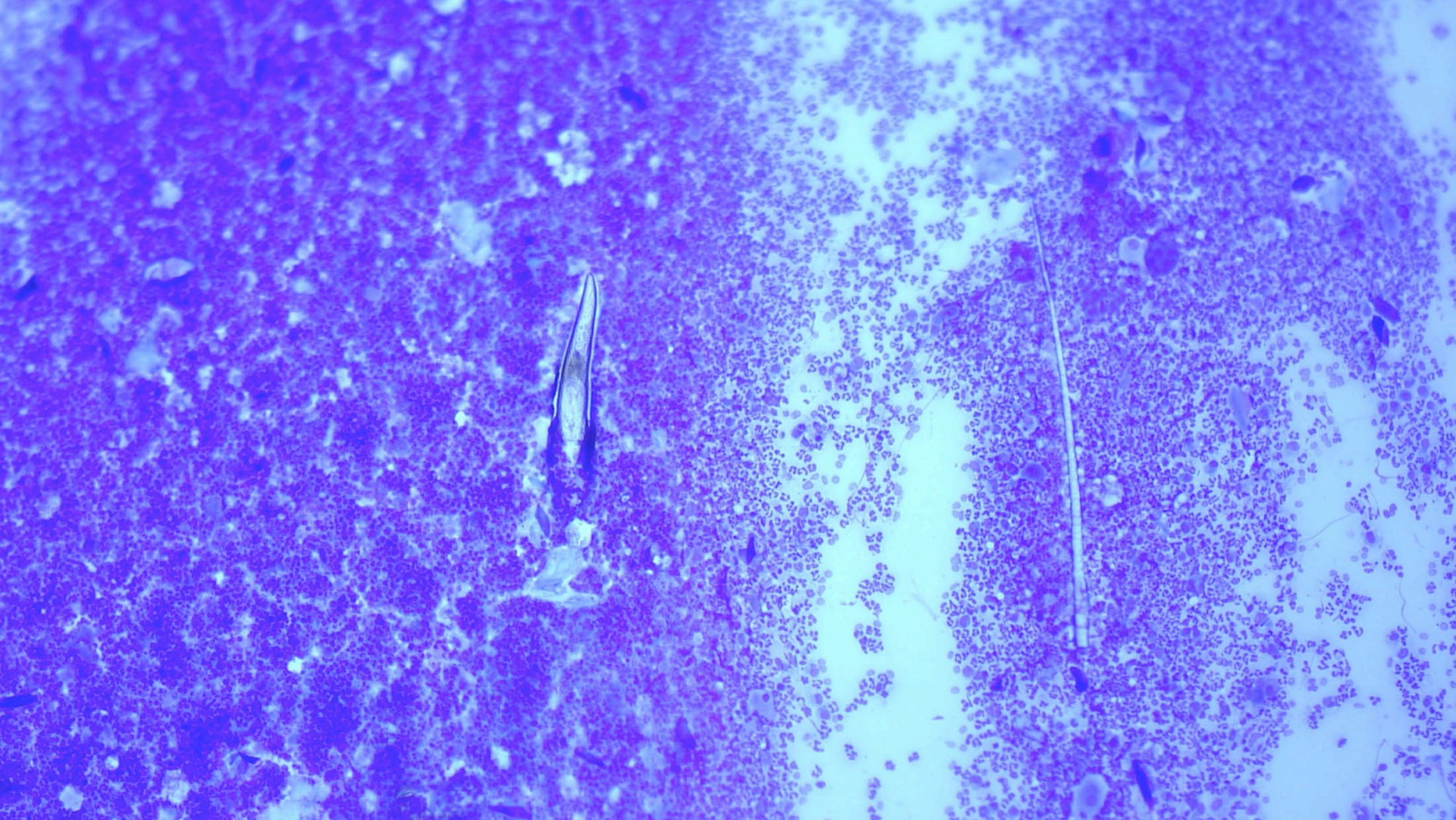




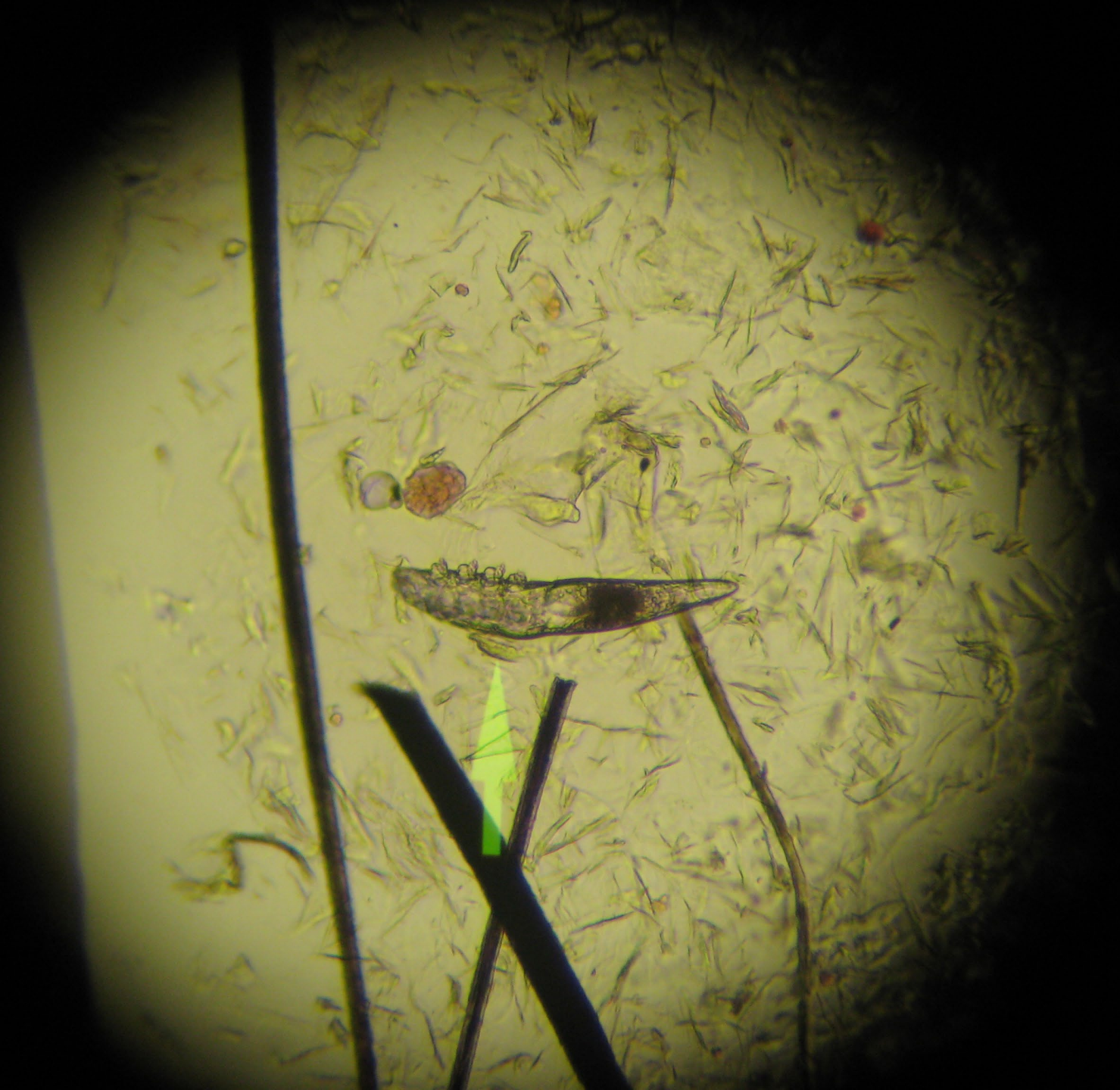


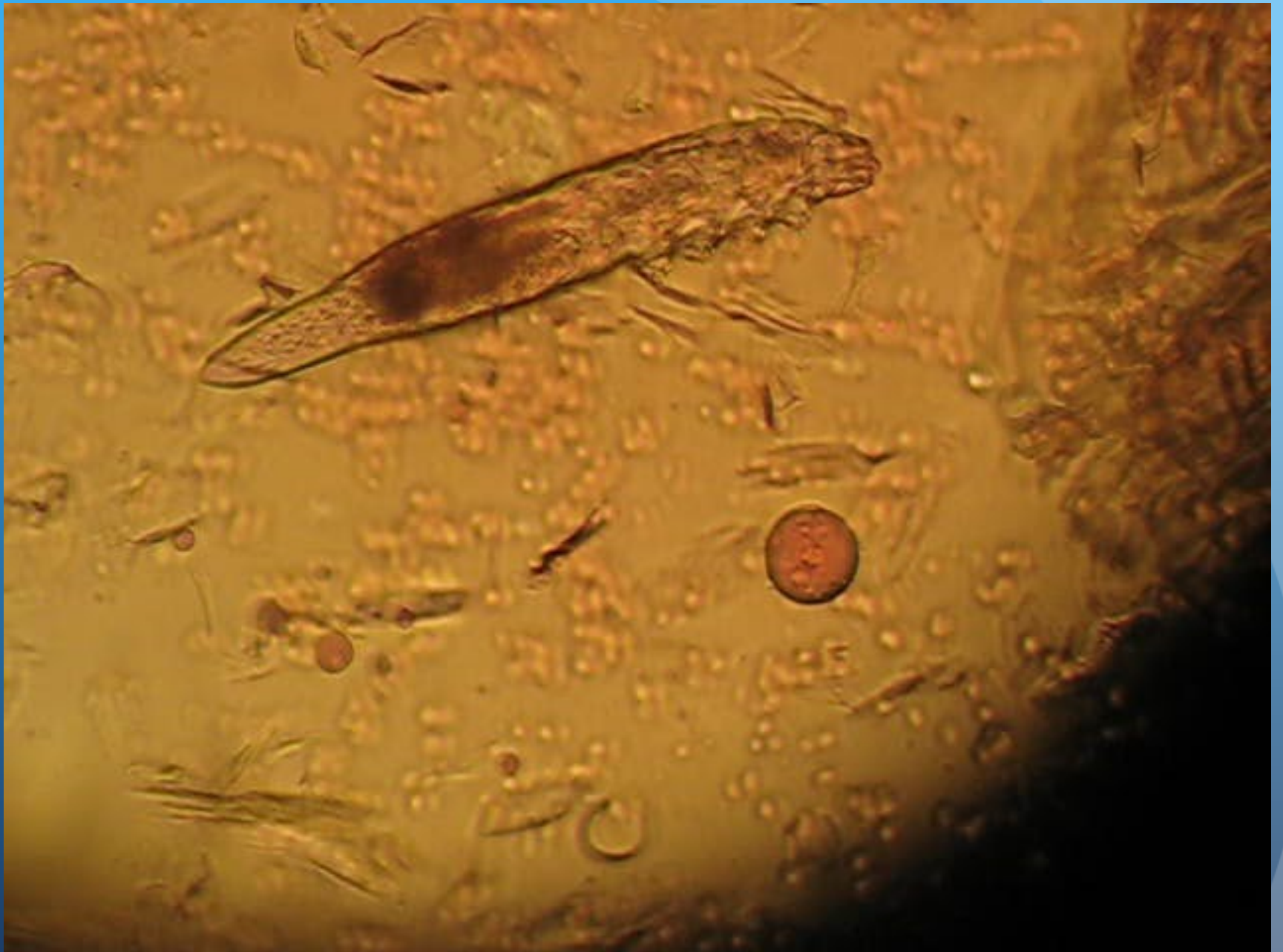
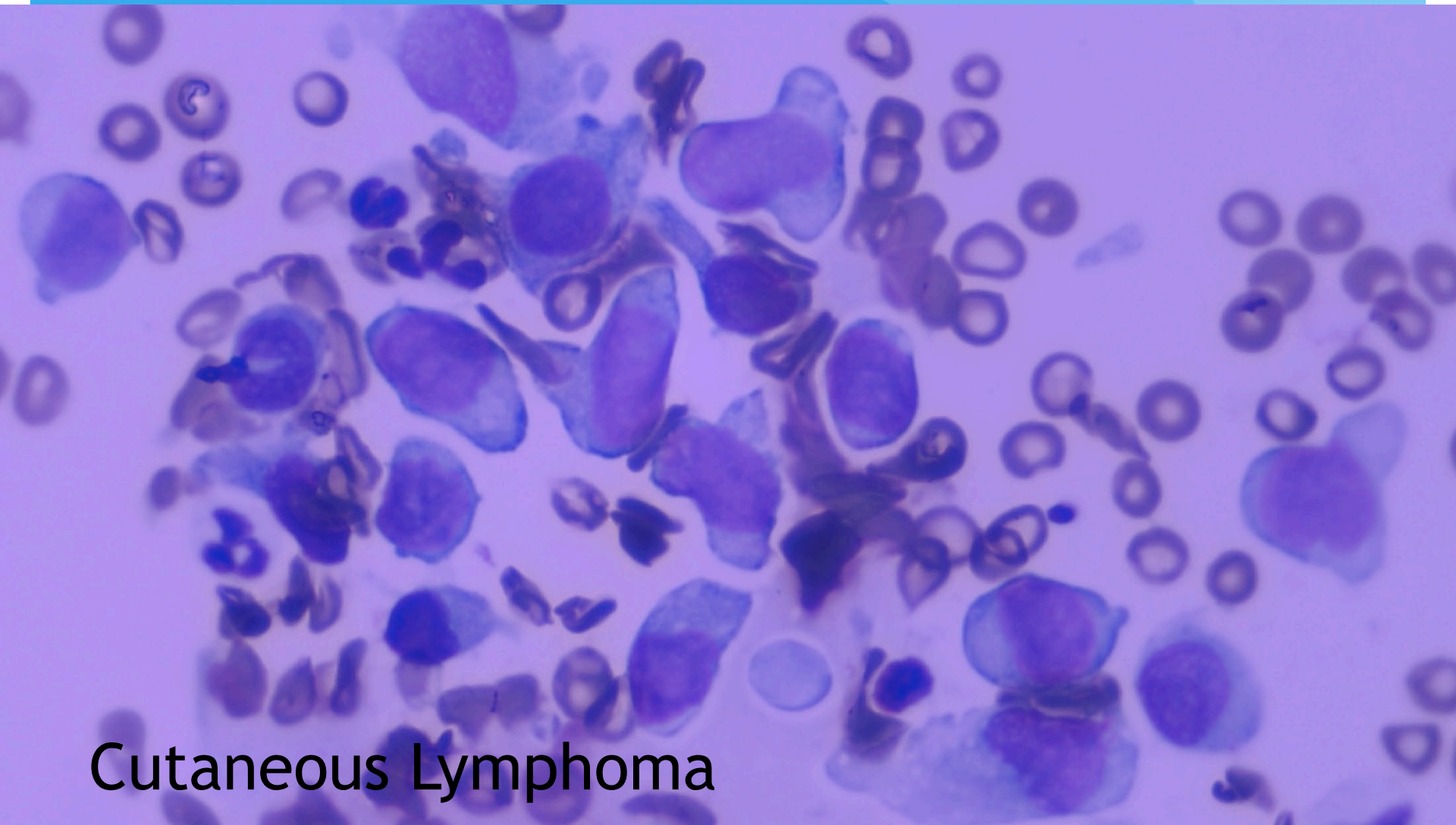






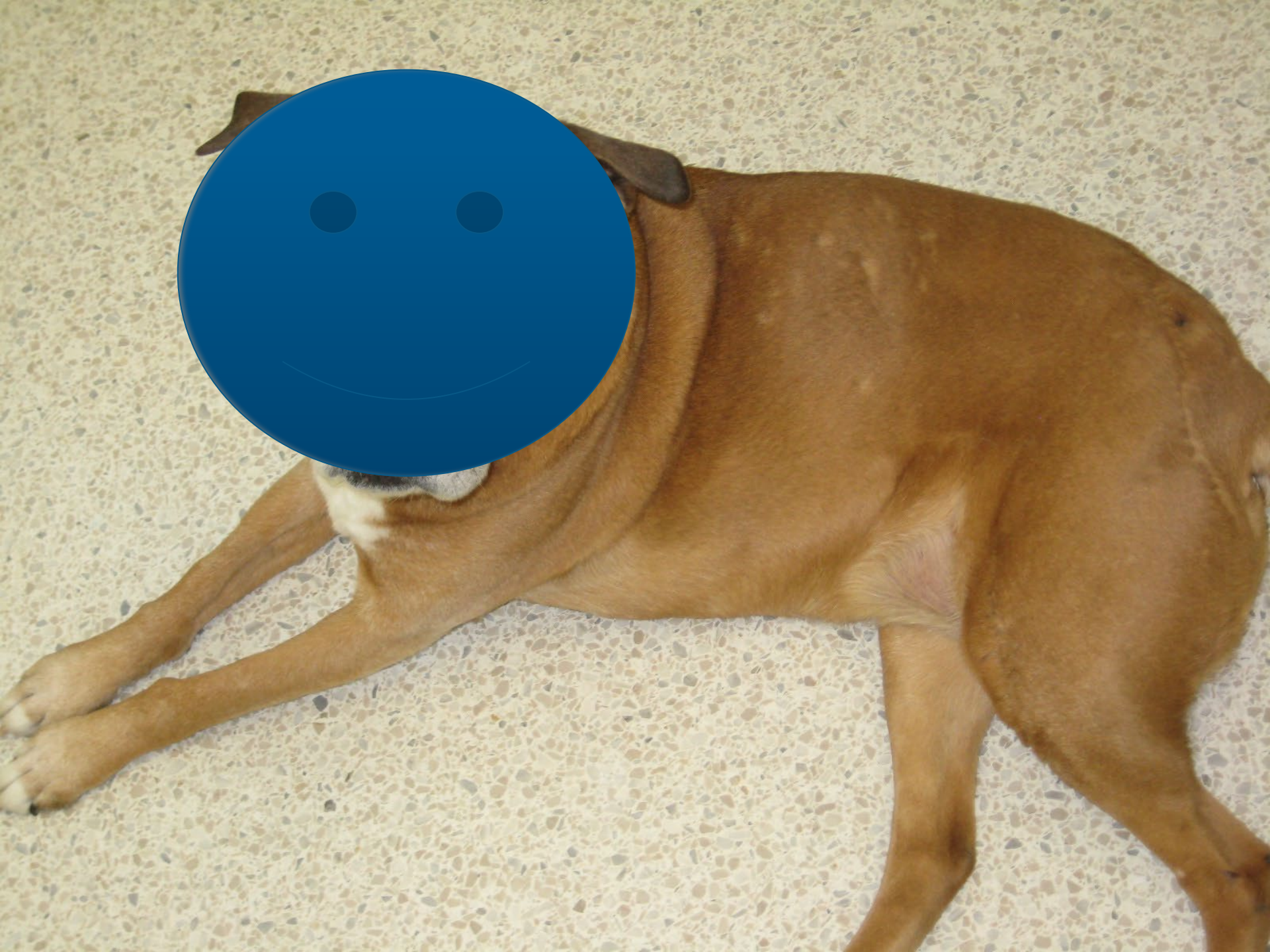

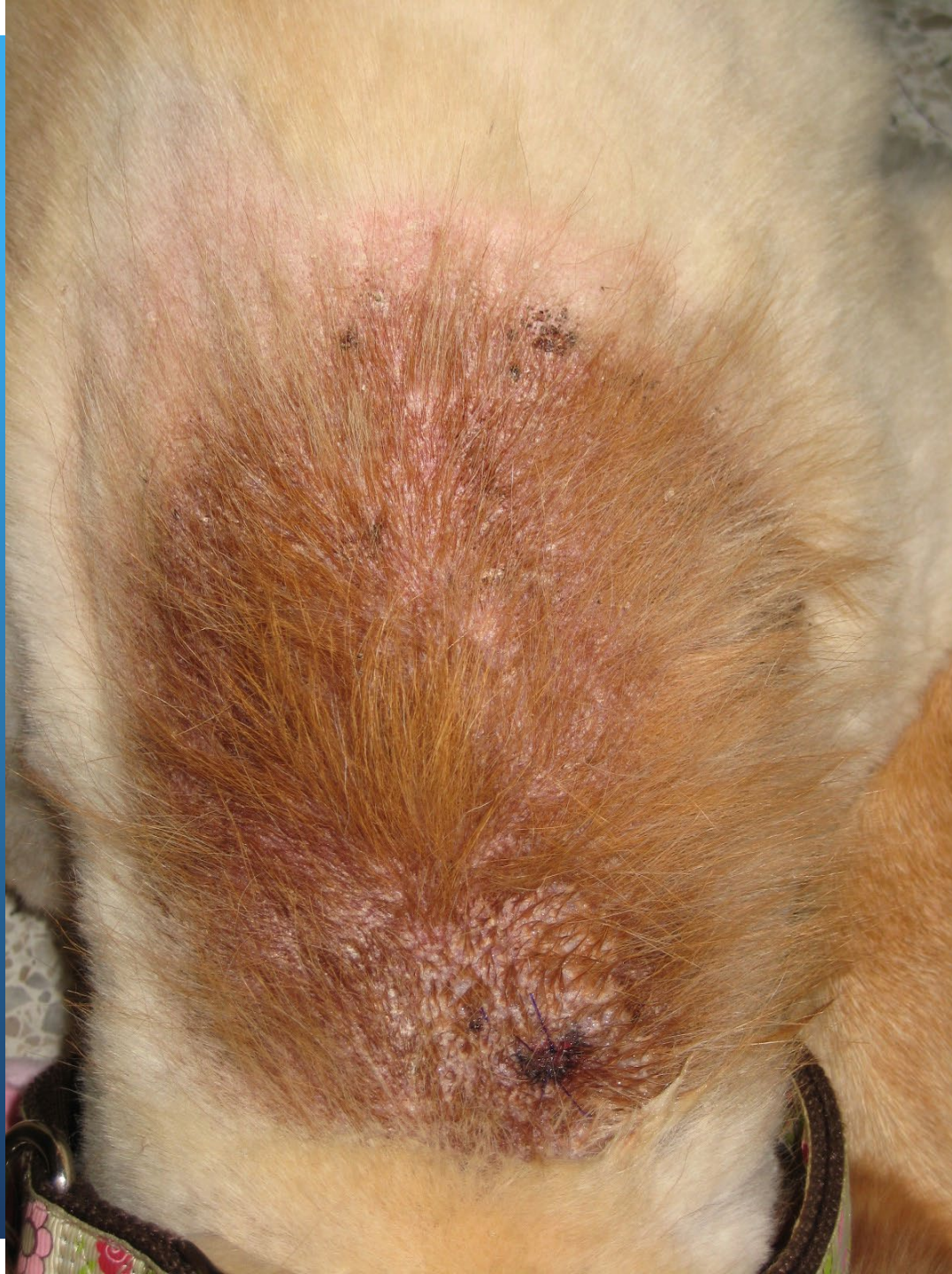




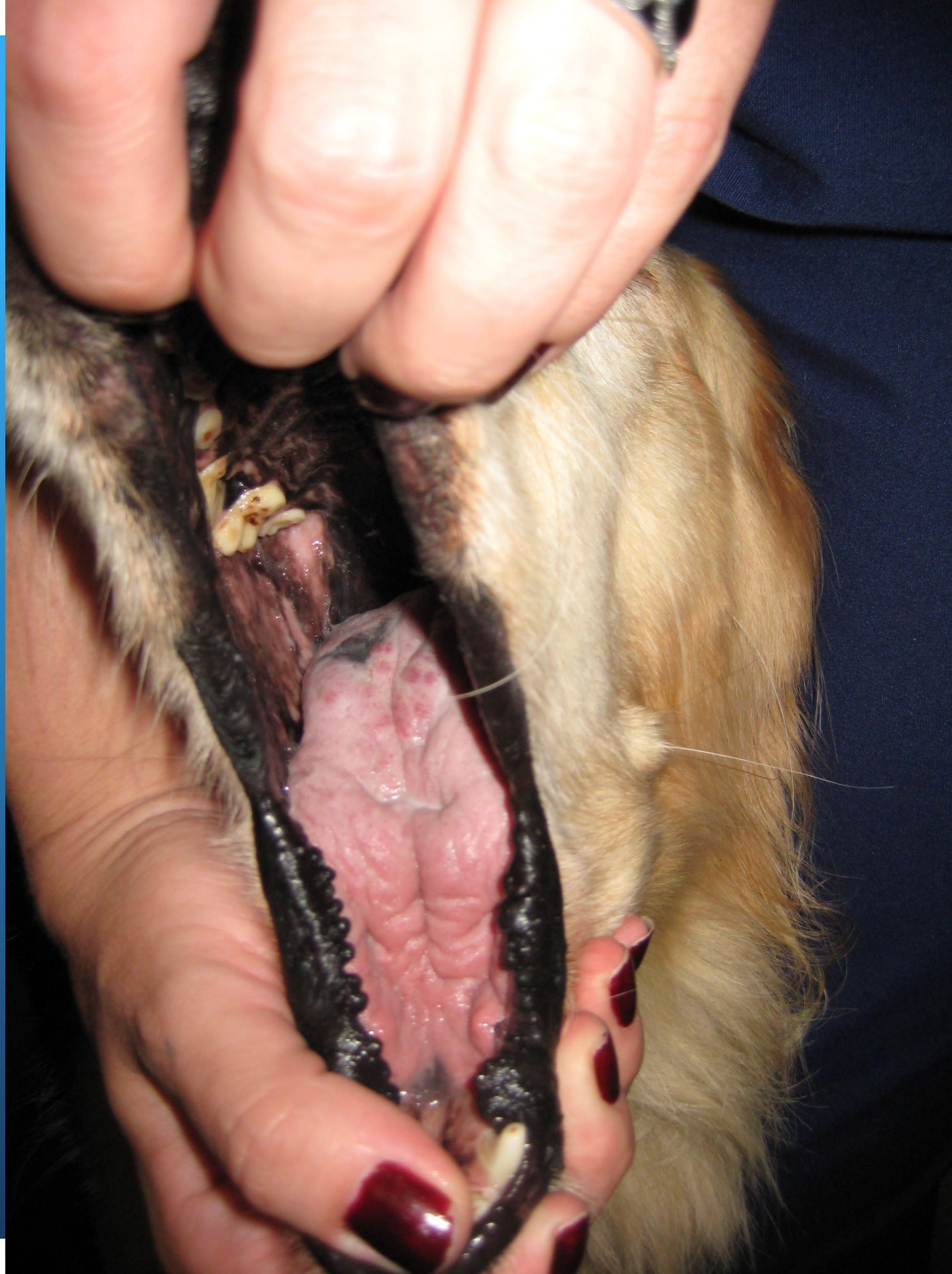Cutaneous Lymphoma

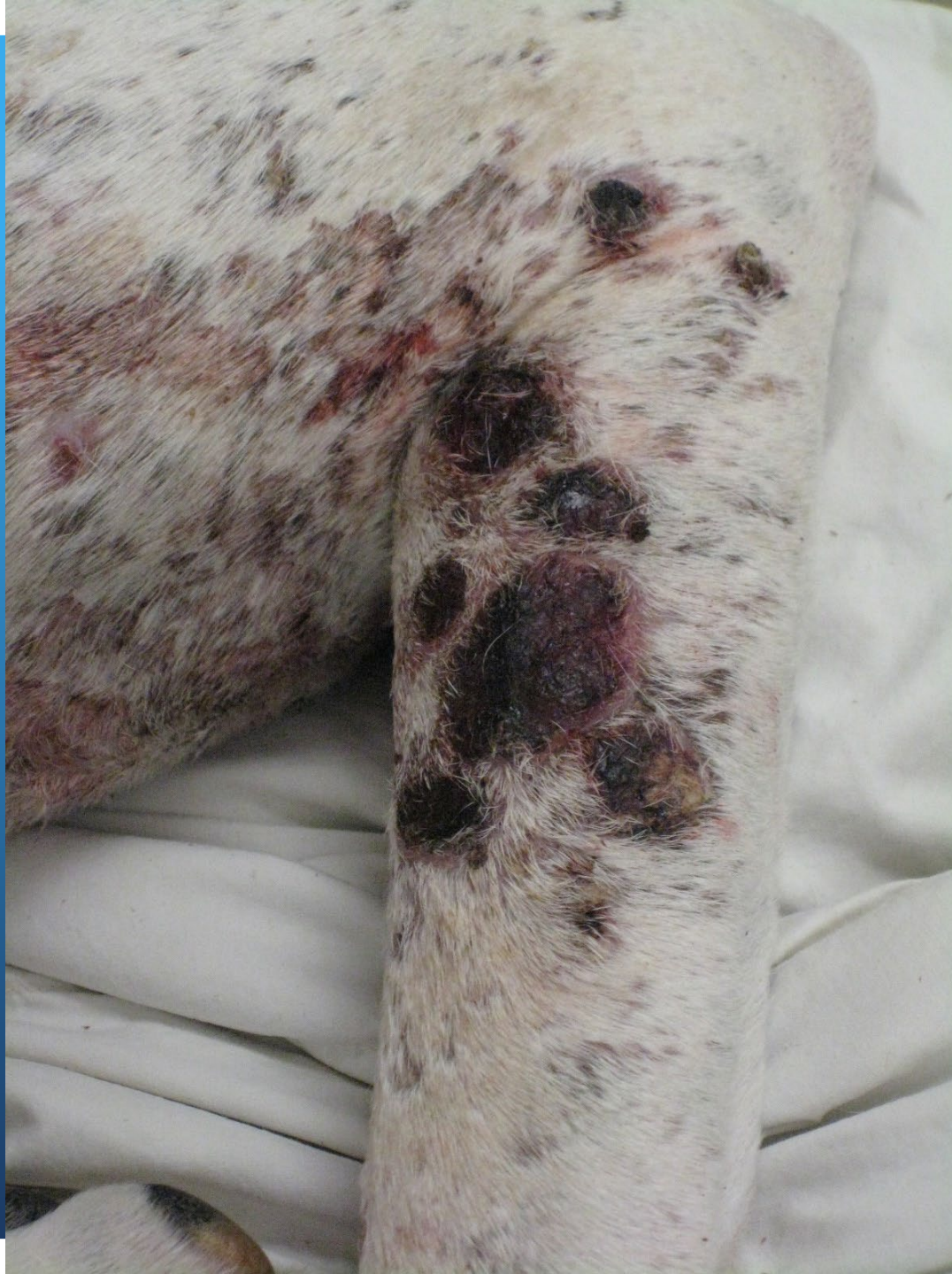


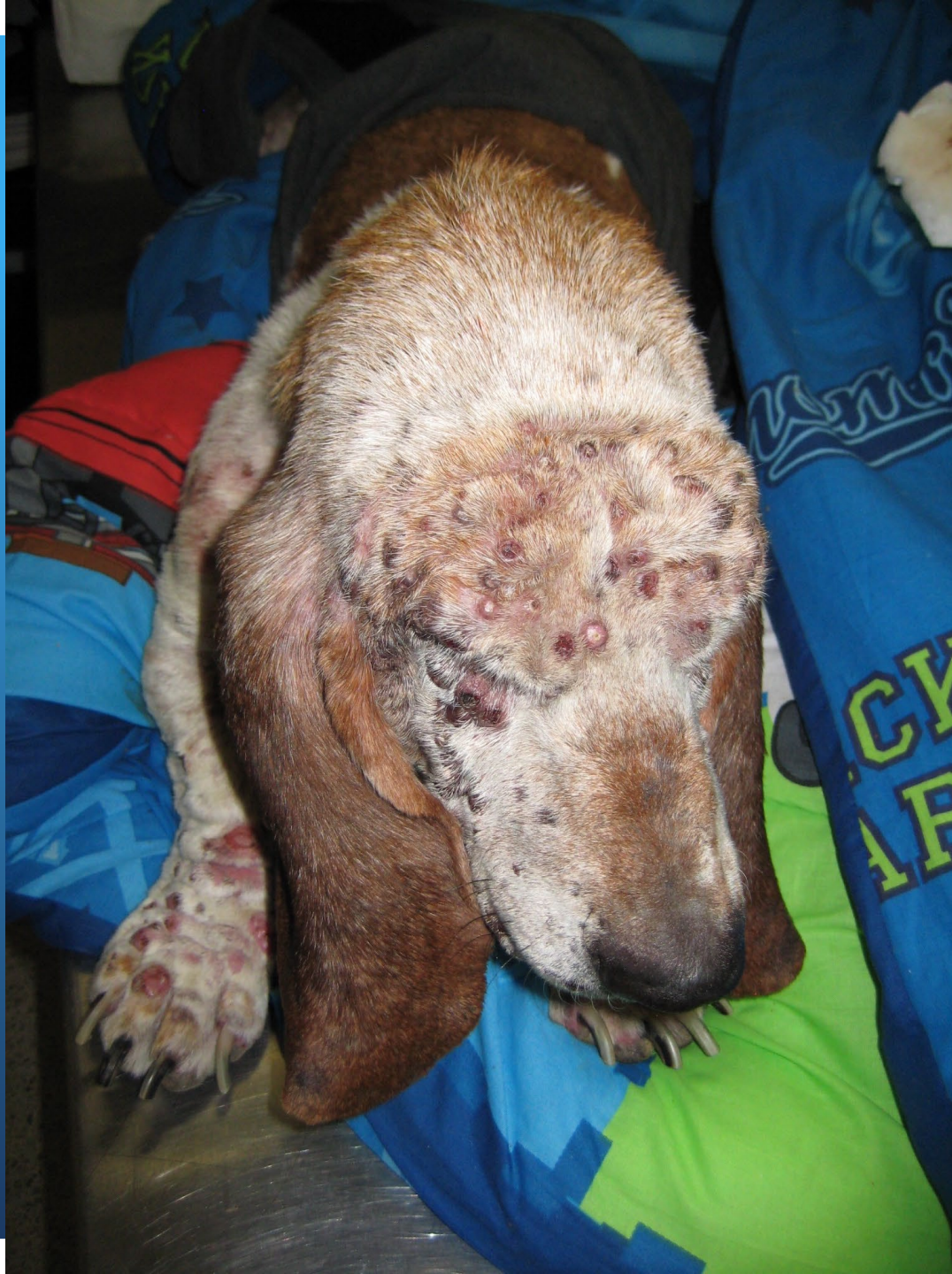
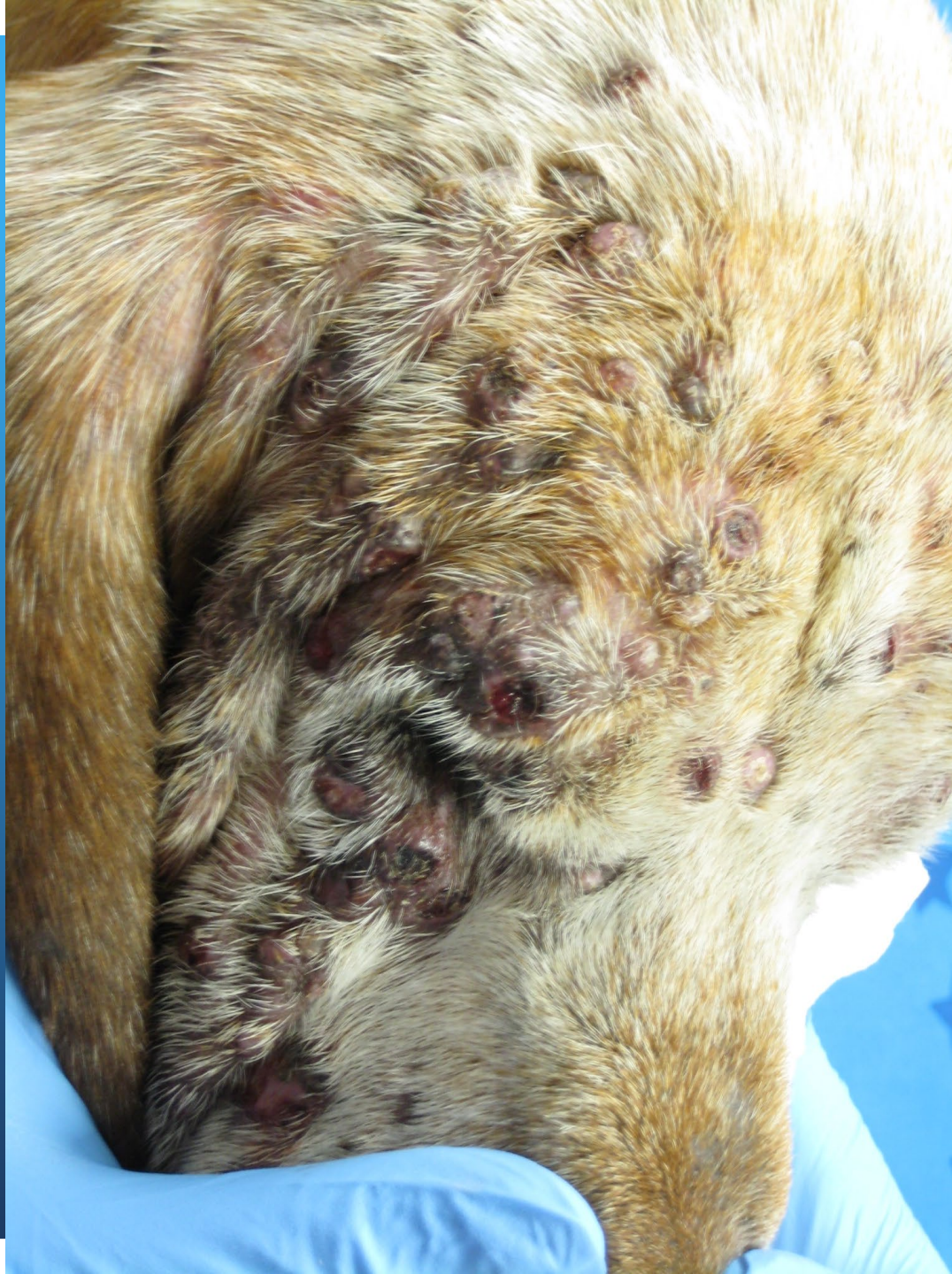












THANK YOU!

Questions???